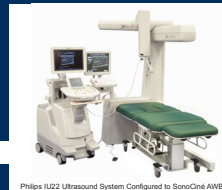

# Early Experience with Automated Whole Breast Ultrasound Screening (AWBUS) as an Adjunct to Mammography in Women with Heterogeneously or Extremely Dense Breast Tissue and a Normal Screening Mammogram

Herron D\*, Satre L, Haines P.

Mercy Womens Imaging Center, Sacramento, CA



Philips IU22 Ultrasound System Configured to SonoCine AWBUS

## Objectives

We endeavored to review our initial clinical experience with those patients supplementally screened with Automated Whole Breast Ultrasound (AWBUS). Our objective was to quantify the clinical utility of this new technology and uncover any potential indicators of its long term success or failure.

## Materials and Methods

We sequentially scanned 173 women with the SonoCine AWBUS system over an approximate six month period beginning July 22, 2013 and ending January 16, 2014. All women scanned had heterogeneously or extremely dense breast tissue, a normal screening mammogram, and were also not at high enough risk to be screened with MRI. Images were acquired in an automated and reproducible fashion and without the intervention of a Radiologist. Several thousand ultrasound images were seamlessly bound together into a cine loop and stored to PACS. The cine loops were then queried, retrieved and read by one of three reading radiologists, each with varying levels of cine loop reading experience. Patients were recalled for diagnostic ultrasound if any area of interest or suspicion was identified. Confirmed areas of suspicion were biopsied and malignancies were confirmed via pathology.

## Results

Of 173 women screened, 40 (23%) were recalled. The rate of recall dropped precipitously for the most experienced reader who recalled 22 of 130 screens (17%). Of the 40 recalled, 6 were eventually biopsied, resulting in two mammographically occult and pathologically confirmed malignancies. Both were IDC with tumor sizes of 1.1cm and 1.4cm in women with heterogeneously dense breasts (BIRADS Composition - 3). The positive predictive value for automated whole breast ultrasound (PPV1) is 5% and the positive predictive value for biopsy (PPV2) is 33%. The cancer detection rate of 2 in 173 women screened can be extrapolated to 11.5 in 1,000.

## Conclusions

The analysis of our early experience utilizing AWBUS supports its clinical utility in identifying mammographically occult cancers in heterogeneously and extremely dense breast women with normal screening mammograms. Our cancer detection rate was noteworthy while our call back rate and PPVs were very acceptable. Importantly, the call back rate decreased significantly relative to the experience of the reader. We would expect this trend to continue. While these data are encouraging, larger numbers will be needed to confirm our findings.

## Case 1

History: 79 year old female with past history of palpable abnormality in right breast with previous normal findings. Negative mammogram 9/23/13 with heterogeneously dense breasts. Referred for AWBUS due to breast density.

SonoCine Findings: 9mm irregular shaped hypochoic mass at 12:30 o'clock position in her right breast.  
Lesion detected: 9mm invasive ductal carcinoma.

Image 1. RCC 9-23-2012, RCC 9-23-2013

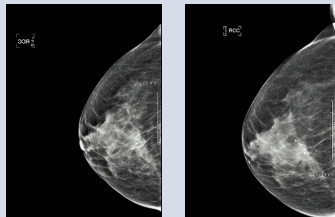


Image 2. AWBUS 10-14-2013 9mm mass at 12:30 o'clock position

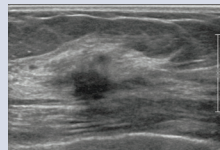


Image 4. Right diagnostic ultrasound 11-1-2013 at 12:30 o'clock position

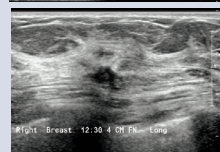
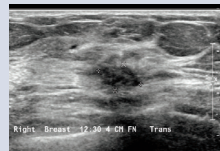
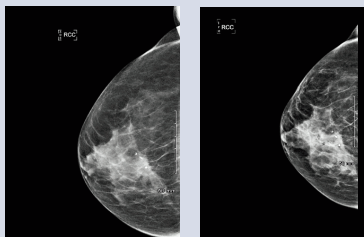


Image 3. RCC 9-23-2013, RCC Post biopsy 11-1-2013 (clip obscured by calcification)



### Findings

Automated Whole Breast Ultrasound Screening: 9mm irregular shaped hypochoic mass at 12:30 o'clock position in right breast  
Pathology: 1.2 x 1.1 CM invasive ductal carcinoma with negative sentinel lymph node

## Case 2

History: 63 year old female with a negative mammogram 11-19-13 referred for a AWBUS due to heterogeneously dense breasts.

SonoCine Findings: 1.5 cm irregular shaped hypochoic mass at 3:45 o'clock position in her left breast.  
Lesion Detected: 1.5 cm poorly differentiated invasive ductal carcinoma.

Subsequent evaluation: Extent of disease MRI demonstrated an enlarged 0.8 x 0.3 x 0.6 probable intramammary lymph node in the left breast and a mildly enlarged left axillary lymph node with irregular cortex 1.2 x 0.7 x 2.0 cm. Subsequent MRI directed second look ultrasound biopsy resulted in an intramammary lymph node negative for malignancy and a left axillary lymph node positive for metastatic breast cancer.

The patient underwent left breast conservation therapy and axillary lymph node dissection.

Image 1. Left cc 11-19-2013, left cc 11-12-2012

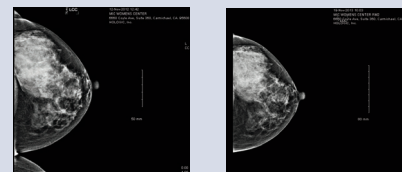


Image 2. AWBUS 11-15-2013 1.5 cm mass at 3:45 o'clock position left breast

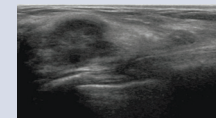


Image 4. Left breast diagnostic ultrasound 11-1-2013 at 3:45 o'clock position

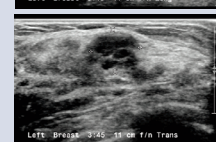
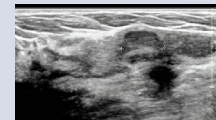
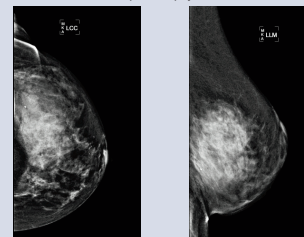


Image 3. Left cc post biopsy 12-6-2013, left mlo post biopsy 12-6-2013



### Findings

Automated Whole Breast Ultrasound Screening: 1.5 cm irregular shaped hypochoic mass at 3:45 o'clock position in her left breast  
Pathology: 1.4 x 1.3CM poorly differentiated invasive ductal carcinoma with a single metastasis to a lymph node in the axilla