



## A DESCRIPTIVE STUDY OF THE RADIOGRAPHIC DENSITY OF IMPLANT RESTORATIVE CEMENTS

Chandur Wadhvani, BDS, MSD,<sup>a</sup> Timothy Hess, DDS,<sup>b</sup> Thomas Faber, DDS, MSD,<sup>c</sup> Alfonso Piñeyro, DDS,<sup>d</sup> and Curtis S. K. Chen, DDS, MSD, PhD<sup>e</sup>  
University of Washington, Seattle, Wash

**Statement of problem.** Cementation of implant prostheses is a common practice. Excess cement in the gingival sulcus may harm the periodontal tissues. Identification of the excess cement may be possible with the use of radiographs if the cement has sufficient radiopacity.

**Purpose.** The purpose of this study was to compare the radiographic density of different cements used for implant prostheses.

**Material and methods.** Eight different cements were compared: TempBond Original (TBO), TempBond NE (TBN), Fleck's (FL), Dycal (DY), RelyX Unicem (RXU), RelyX Luting (RXL), Improv (IM), and Premier Implant Cement (PIC). Specimen disks, 2 mm in thickness, were radiographed. Images were made using photostimulable phosphor (PSP) plates with standardized exposure values. The average grey level of the central area of each specimen disk was selected and measured in pixels using a software analysis program, ImageTool, providing an average grey level value representative of radiodensity for each of the 8 cements. The radiodensity was determined using the grey level values of the test materials, which were recorded and compared to a standard aluminum step wedge. An equivalent thickness of aluminum in millimeters was calculated using best straight line fit estimates. To assess contrast effects by varying the exposure settings, a second experiment using 1-mm-thick cement specimens radiographed at both 60 kVp and 70 kVp was conducted. The PSP plates with specimens were measured for a grey level value comparison to the standard aluminum step wedge, using the same software program.

**Results.** The highest grey level values were recorded for the zinc cements (TBO, TBN, and FL), with the 1-mm specimen detectable at both 60- and 70-kVp settings. A lower grey level was recorded for DY, indicative of a lower radiodensity compared to the zinc cements, but higher than RXL and RXU. The implant-specific cements had the lowest grey level values. IM could only be detected in 2-mm-thick sections with a lower aluminum equivalence value than the previously mentioned cements. PIC could not be detected radiographically for either the 1-mm or 2-mm thicknesses at either of the kVp settings.

**Conclusions.** Some types of cement commonly used for the cementation of implant-supported prostheses have poor radiodensity and may not be detectable following radiographic examination. (J Prosthet Dent 2010;103:295-302)

### CLINICAL IMPLICATIONS

Removal of excess cement may be facilitated if it can be detected radiographically. Knowledge of the different radiodensities of cements used for implant prostheses may assist the clinician in selecting an appropriate cement.

<sup>a</sup>Affiliate Faculty, Department of Restorative Dentistry; private practice, Bellevue, Wash.

<sup>b</sup>Private practice, Auburn, Wash.

<sup>c</sup>Affiliate Professor, Department of Periodontology; private practice, Seattle, Wash.

<sup>d</sup>Affiliate Faculty, Department of Restorative Dentistry; private practice, Bellevue, Wash.

<sup>e</sup>Professor and Director, Division of Radiology, Department of Oral Medicine.



Use of endosseous implants to replace missing teeth is a common and accepted procedure.<sup>1</sup> Restorations placed on the implants are generally classified as either screw or cement retained. Early procedures relied almost entirely on screw retention; however, limitations due to screw loosening, passive fit, implant angulation, and esthetics have resulted in the increased use of cementation.<sup>2</sup> Cementation procedures are more similar to procedures used for traditional dental restorations, enabling dentists to use techniques that have been established for tooth-supported restorations.

Cement-retained implant restorations are not without issues. A study<sup>3</sup> comparing periimplant soft tissues of cement-retained and screw-retained restorations reported poorer soft tissue health associated with cement-retained restorations. Clinical reports have documented the adverse effects of excess cement extruded into the periimplant soft tissues.<sup>4,5</sup> Excess cement contributed to over 80% of periimplant disease documented in one study.<sup>6</sup> Several novel techniques have been described to assist in minimizing excess cement extrusion.<sup>7-9</sup> However, if cement is inadvertently expressed into the periimplant tissues or left as a cement overhang, it should be readily detected and removed.

Techniques have been described for locating the excess cement around implant restorations with the use of a dental endoscope,<sup>6</sup> or, more invasively, with open flap debridement, which allows direct observation.<sup>4,5</sup> Radiographic examination is less invasive and has been shown to be useful in the identification of cement overhangs associated with tooth-supported restorations.<sup>10,11</sup>

Recommendations have been made with respect to radiodensity levels of dental materials used to restore or cement restorations on teeth.<sup>12-14</sup> A variety of cements are currently available for restorative procedures.<sup>7</sup> Most are primarily designed for use with teeth and may be classified according to physical properties,

material content, and the purpose for which they were designed, for example, interim, provisional, or definitive. Some cements have unique properties such as adhesion to tooth tissue, anticaries activity, and ion exchange. Implant-specific cements have also been formulated with useful properties relevant to implants, such as adherence to metal abutments, ease of removal of excess cement, and retrievability.

Either implant-specific cements or traditional restoration cements may be used for cementing implant restorations. These cements have been extensively assessed in terms of mechanical properties,<sup>15-20</sup> including retention capabilities, when used for implant procedures. Cement has also been shown to extrude at the implant abutment-interface when subgingival margins are present. One study<sup>21</sup> reported on the ease of excess cement removal as well as the damage caused to the titanium abutments by various instruments used in the process. There have been no reports specific to the radiographic characteristics of cements used for implant restorations. Selection of cements should involve knowledge of the ability to detect excess cement; it is also important that a clinician be able to confirm that the cemented units are correctly positioned. Both the presence of excess cement and correct positioning could potentially be determined by noninvasive radiographic examination, provided materials in question show the appropriate radiographic density (radiodensity).

Several factors may affect the radiodensity of cements; composition is probably the most significant. In addition, the material thickness, exposure settings, angulation of the x-ray beam, and the methodology used for evaluation have all been documented as factors.<sup>22-25</sup> Radiographic images made from x-ray exposure of a digital receptor produce a spatial distribution of picture elements, or pixels. Each pixel has an associated pixel value or number that ranges from 0-255 for an 8-bit image. The pixel value may be translated into brightness or grey level, which can be recorded and

measured and is representative of radiographic density.

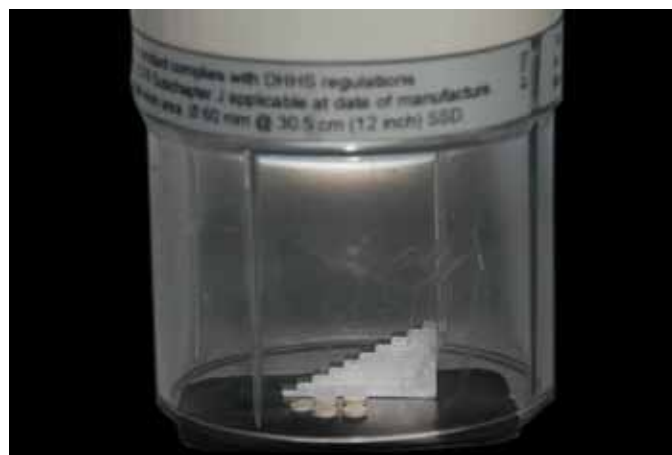The purpose of this study was to evaluate and compare, using grey level values, the radiodensity of cements commonly used for implant cementation procedures. Two thicknesses of cement were compared for threshold grey levels. The study also compared cement specimens at different x-ray exposure settings to determine if contrast differences influenced radiographic detection.

## MATERIAL AND METHODS

Eight cements were evaluated (Table 1). Standardized specimens of each material were produced in accordance with the manufacturers' instructions. The cements were mixed and then loaded into a 1.2-ml plastic syringe (Ultradent Products, Inc, South Jordan, Utah) within the respective specimen's working time. Nylon spacers (Hillman Group, Cincinnati, Ohio), with internal measurements of 5 mm in diameter and 2 mm in thickness, were placed on a clean sheet of glass. The centers of the nylon spacers were filled with cement extruded from the syringe to minimize air voids. A second sheet of glass was placed on top of the filled spacers to express excess material, and the cement was allowed to set at room temperature. The glass sheets were separated and the nylon spacer/cement complex removed. The nylon spacers were carefully removed, leaving a cement disk which was evaluated for voids and inconsistencies. The thickness of the disk near its center was measured with a digital micrometer (293-761; Mitutoyo Corp, Kanagawa, Japan) to ensure specimens had a thickness range of  $2 \pm 0.1$  mm. Five disks for each of 8 cements were produced. A second set of 5 disks was fabricated in a similar manner, but with a thickness of  $1 \pm 0.1$  mm. Each set of 5 disk specimens was carefully placed on the surface of a size-2 intraoral photostimulable phosphor imaging plate (ScanX; Air Techniques, Inc,

**TABLE I.** Cements evaluated

Commercial Name	Manufacturer	Batch Number	Type
Dycal (DY)	Dentsply Intl, York, Pa	60552	Calcium hydroxide
Fleck's (FL)	Mizzy, Inc, Cherry Hill, NJ	L75	Zinc phosphate
Improv (IM)	Alvelogro, Snoqualmie, Wash	DP-1/072508	Resin
Premier Implant Cement (PIC)	Premier Products Co, Plymouth Meeting, Pa	4135C1	Resin
RelyX Luting (RXL)	3M ESPE, St. Paul, Minn	20081223	Glass ionomer
RelyX Unicem (RXU)	3M ESPE	355877	Universal resin
TempBond Original (TBO)	Kerr Corp, Orange, Calif	8-1303	Zinc oxide/eugenol
TempBond NE (TBN)	Kerr Corp	8-1306	Zinc oxide/noneugenol

**1** Specimen disks with modified step wedge.**2** Radiographic unit and image plate.


Melville, NY). A 98% pure aluminum step wedge (DHEF, Inc, Taipei, Taiwan) was placed adjacent to the specimens, near the center of the PSP image plate (Fig. 1). The wedge increased in incremental, millimeter-thick steps from 1 mm to 10 mm.

A single intraoral x-ray machine (Focus; Instrumentarium Dental, Tuusula, Finland) was used. The x-ray exposure was set at 70 kVp, 0.32 seconds, and 7 mA, and a 300-mm focus film

distance (FFD) was used for all specimens. The x-ray beam was maintained perpendicular to the specimens, which were placed on the imaging plates<sup>22</sup> (Fig. 2). Radiographic images were made of each cement (Fig. 3). Following exposure, the PSP image plate was immediately placed in the digital reader (ScanX; Air Techniques, Inc), and the images were scanned at an average resolution of 21 pixels/mm. Images with 8-bit grey

level resolution were generated. Grey levels range from 0 (black, representing a radiodensity level of 0) to 255 (white, representing the highest possible radiodensity). The images were processed with ScanX-compatible software (PatientGallery; Raster Builders, Inc, Greenbrae, Calif).

Eight test cements with 5 disks on each plate yielded 40 specimens for data collection. No power analysis was performed to determine ad-



**3** A, TempBond Original, 2-mm specimen image at 70 kVp. B, Premier Implant Cement, 2-mm specimen image at 70 kVp.

equate sample size. To reduce reading errors due to sensor inhomogeneity, a minimum number of disks were used.<sup>23</sup> Five disks were deemed the appropriate number which would fit most easily on the PSP plate next to the aluminum step wedge. Each exposure was made with the disks placed in approximately the same position on the PSP plate, near the center. To minimize peripheral effects, pixels were sampled from the central area of each specimen. Each disk was read 3 times, and the average value was calculated for the 2-mm-thick cement specimens. The average grey level value of the specimens was determined using an image processing and analysis program (ImageTool Version 2.0; University of Texas, San Antonio, Tex). Each cement disk occupied an area of approximately 8000 square pixels. A central area of approximately 2000 pixels was selected and measured with the imaging tool, providing an average pixel grey level value representative of radiodensity. The grey level values of the materials were recorded and compared to those of a standard aluminum step wedge with incremental, 1-mm steps. An equivalent thickness of aluminum in millimeters was calculated using best straight line fit estimates in which the grey level for the specimens was between steps. For specimens that had values below the lowest observable step value and above the background value, a straight line fit was also used,

with the recognition that an error of estimation would exist. All interpretations were made by a single examiner.

To evaluate contrast differences that could provide clinical guidance<sup>23</sup> on the most appropriate x-ray exposure setting, a second experiment was conducted<sup>24</sup> with the ISO 4049<sup>25</sup> recommendation of 1-mm-thick specimens exposed with x-rays at  $65 \pm 5$  kVp. Five disks (1 mm thick for each material) were subjected to an exposure of 60 kVp and 7 mA, for 0.63 seconds, with the PSP plate as described for the initial experiment. Both the kVp and time settings are preset on the Focus x-ray machine (Instrumentarium Dental) and represent the exposure settings for the maxillary molar. The PSP image plate, once scanned, was subjected to similar data analysis, with the center 2000 pixels selected and measured for the average pixel grey level value. The data were recorded and compared to results produced by exposure of the specimens on the PSP plate at 70 kVp and 7 mA for 0.32 seconds.

Both the 2-mm-thick disks and the 1-mm-thick disks were evaluated for grey level value to determine their radiodensity as defined by their equivalent thickness in aluminum. As several of the cements were not detectable for measurement, a descriptive analysis was used rather than a statistical analysis.

## RESULTS

The specimens were rank ordered based on radiodensity, from highest to lowest grey level values distinguishable from the background. A comparison to the aluminum step wedge standard was recorded. The effect of changing exposure settings from 70 kVp to 60 kVp with preset times to evaluate contrast changes was also recorded. Table II compares the aluminum equivalent thickness as found for 2-mm-thick and 1-mm-thick specimens at different exposure settings (2 mm at 70 kVp for 0.32 seconds, 1 mm at 70 kVp for 0.32 seconds, and 1 mm at 60 kVp for 0.63 seconds).

## DISCUSSION

Currently, no clinical guidelines for implant cementation procedures exist. While some cementation-specific techniques have been described, there is little agreement on the type of cement to use, the ideal depth of implant platform placement, or the position of the cement finish line for optimum tissue health. There are anatomical and clinical differences that render the cemented implant restoration more vulnerable to the effects of foreign materials left adjacent to the surrounding soft tissues.

The soft tissue attachment to a tooth is vastly different than that to an implant. For a tooth with a healthy periodontium, there is a junctional

**TABLE II.** Results: radiographic aluminum equivalence values for cements

Material	Aluminum Equivalent Thickness (mm)		
	2-mm Specimen 70 kVp	1-mm Specimen 70 kVp	1-mm Specimen 60 kVp
TBO	8.11	4.52	4.53
TBN	7.13	3.65	3.64
FL	6.58	3.53	3.54
DY	3.78	1.39	ND
RXU	2.88	ND	ND
RXL	2.58	ND	ND
IM	2.29	ND	ND
PIC	ND	ND	ND

ND: not distinguishable from background

epithelium coronally and a well organized connective tissue attachment apically, which includes gingival fibers penetrating directly into cementum on the root surface. Implants have a less robust attachment that consists of a junctional epithelial attachment coronally and an area of connective tissue contact apically. The junctional epithelium has hemidesmosomal attachment; the connective tissue contact does not have fibers penetrating into the surface of the implant or abutment. The weaker implant/abutment-to-periimplant soft tissue attachment system may be more readily compromised by excess cement extruded into the sulcus. The need to detect excess cement is therefore of concern; if it cannot be detected and removed it may compromise the implant itself, with disastrous effects.<sup>4-6</sup> Deep subgingival margin placement is likely to make it difficult to detect excess cement near the margins by either tactile or visual means.<sup>4,21</sup> The feasibility of removing excess cement on the abutment/implant unit has also been investigated; zinc phosphate was reported to be the easiest and resins the most difficult cements to remove.<sup>21</sup> The authors of the same study also reported on the damage caused to the titanium abutments

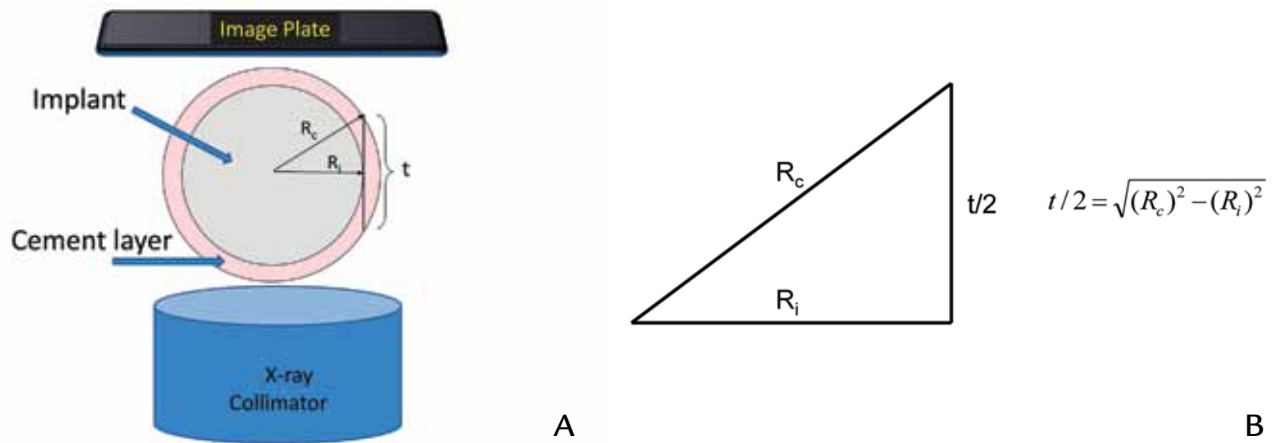
by various instruments used to remove excess cement. A stainless steel explorer left the deepest scratches on the abutment surfaces, while plastic scalers caused the least damage. A rough abutment/implant surface may result in increased plaque accumulation, impaired plaque removal, and compromised soft tissue compatibility.<sup>4,21</sup>

The most likely genesis of periimplant disease when excess cement is present is microbial colonization of the rough cement surface, as its roughness limits the ability to clean it.<sup>6</sup> This would explain why effects are seen some time after the restoration is completed. Two reports have documented that periimplant disease occurs from a few weeks to several years following implant restoration.<sup>4,6</sup> Dental cements are constantly being reformulated to improve their properties. One desirable property is radiodensity or radiopacity<sup>10-14</sup> (a term used when viewing conventional radiographic film), particularly in evaluating residual excess cement in subgingival areas.

There were notable differences when comparing the grey levels of different cements in this study. Of the 8 cements evaluated, the highest grey level values were recorded for the zinc-containing materials (TBO, TBN, FL),

which was expected due to zinc's high atomic number and electron density. In contrast, DY, which is composed of calcium hydroxide, had a lower gray level value. The zinc-containing cements may also offer other advantages. They may be either interim, such as the TBO and TBN varieties tested, or definitive, as is FL, allowing a choice of cement retention capabilities.<sup>15-19</sup>

The glass ionomers and resin cements are expected to have poor radiodensity properties unless specific radiopacifiers are added during formulation. This was reflected in the specimens, with RXL and RXU demonstrating less radiodensity than DY, with a lower gray level value. IM could only be detected in the 2-mm-thick specimens, indicating a lower radiodensity than either RXL or RXU. PIC was indistinguishable from the background with the imaging system used. The use of the resins and glass ionomer specimens selected can be considered problematic, as some excess material may occasionally be left in the implant soft tissue sulcus. If the tangential thickness (Fig. 4, A) is less than 1-mm, then cements RXL, RXU, or IM would be difficult, if not impossible, to detect by radiographic means.



**4** A, Schematic and calculation for tangential thickness of cement. B,  $R_i$ : Implant radius;  $R_c$ : Implant plus cement layer;  $t$ : tangential depth.

The frequency and volume of excess cement found remaining in the periimplant tissues have yet to be evaluated. It is anticipated that this would vary according to many factors, including depth, volume of cement within the crown, viscosity of the cement, resistance to flow within the sulcus, and the manner in which the cementation procedure is performed. The use of 1-mm-thick and 2-mm-thick specimens is intended to indicate threshold radiographic grey level values that may have clinical significance. Excess cement can flow circumferentially around the abutment or implant within the sulcus, forming a film or layer of cement. This layer is visible when viewed tangentially on the side of implants or abutments (Fig. 4, A), and the tangential thickness of the layer can be calculated (Fig. 4, B). This tangential thickness has been described as the “eggshell” effect,<sup>26</sup> an example of which is commonly seen as the lamina dura on radiographs of tooth sockets. It is clear from the calculations that a surface diameter of 5 mm with a cement layer of as little as 0.2 mm may easily approach 2 mm in tangential depth (Table III). Using 1-mm and 2-mm specimens in the present study allowed comparison to other studies,<sup>10,11</sup> which also reported on the radiographic detection of overhangs from luting agents. The results were similar, although comparison is difficult as the materials studied were not identical.

Extrusion of cement into the soft tissues has been described as common to tooth restorations<sup>10,11</sup> as well as to implants.<sup>4-6</sup> In both instances, radiographic examination may help to detect the excess cement, provided the luting agent presents high enough radiodensity levels.<sup>15</sup> For teeth, some authors suggest that the cement be similar in radiopacity to dentin to allow carious dentin to be detectable; others recommend higher radiodensity, closer to that of enamel.<sup>10-13</sup> Caries is not an issue when considering implants, and a reference should be established with respect to titanium or other metals used for implant restorations. It is proposed that the luting agent should be more radiographically dense than the titanium alloys used.

The areas where cement extrusion is most likely to be seen radiographically are the proximal areas, if an orthogonal projection (film parallel to the implant and with the radiographic tube parallel to the jaw axis) is produced. The tube angulation has an effect on radiographical analysis and should be positioned within 5 degrees of the stated projection.<sup>22</sup> The facial and lingual areas would be obstructed by the implant/abutment complex, which may be less of an issue as these areas can often be accessed to remove excess cement most easily. In the proximal areas, where papillae are often present, it is reasonable to assume that the cement would be most difficult to detect

clinically and remove, not only due to adjacent dentition, but also due to deeper implant margins. For these reasons, it would seem that the most critical area to detect excess cement is the area where radiographic imaging has its maximum benefit, which is on the proximal surfaces. Postcementation protocols do not presently include radiographic examination. Radiographic evaluation after second-stage implant surgery to verify the positions of the implants and the implant-abutment fit, as well as immediately after prosthesis connection, has been suggested.<sup>22</sup> However, current ADA guidelines do not recommend routine radiographs for implants; rather, that clinical judgment be used in determining the need for and type of radiographic images necessary for evaluation and/or monitoring in these circumstances.<sup>27</sup> If there is any concern that excess cement remains around the prosthesis, and if the cement is radiopaque, then the use of a radiograph is recommended. An understanding of the radiographic property of the cement chosen, as well as interpretation of the effects that a film thickness can produce, is a clear advantage.

The importance of postoperative appointments for implant patients following cementation of the restoration has been suggested. The first visit should be scheduled no later than 1 week after cementation to detect early changes or reactions of the



**TABLE III.** Tangential cement thicknesses for different implant diameters and cement film thickness

Implant Diameter (mm)	Implant Radius ( $R_i$ ) (mm)	Cement Film Thickness ( $R_c$ ) (mm)	Tangential Cement Thickness ( $t$ ) (mm)
3.5	1.75	0.1	1.20
3.5	1.75	0.2	1.72
3.5	1.75	0.3	2.14
3.5	1.75	0.4	2.50
3.5	1.75	0.5	2.83
4	2	0.1	1.28
4	2	0.2	1.83
4	2	0.3	2.27
4	2	0.4	2.65
4	2	0.5	3.00
5	3	0.1	1.43
5	3	0.2	2.04
5	3	0.3	2.52
5	3	0.4	2.94
5	3	0.5	3.32

periimplant tissues.<sup>4</sup> These changes include clinical signs of inflammation, bleeding on probing, and presence of exudate. The patient's concerns and related symptoms are also important, as they may prompt clinical and radiographic evaluation. Following the first postoperative visit, the patient should be seen at 1-, 3-, and 6-month intervals after placement of the restoration, or sooner if there are concerns. Should periimplant complications suggest the possibility of residual excess cement, radiographs could provide useful information, particularly if the cement is radiographically dense enough to contrast with its surroundings. Treatment may include conservative exploratory surgery to confirm the initial diagnosis and evaluate the extent of the problem, removal of the excess cement, local curettage, regenerative therapies, and replacement of the existing restoration, if indicated, to restore the health of the surrounding tissues.

ISO standard 4049<sup>25</sup> states that the radiopacity of the material (if pur-

ported by the manufacturer) should be at least the same as the equivalent thickness of aluminum when irradiated at 65 kVp  $\pm$  5 kVp. The radiographic unit used in the current study allows the user to vary the kilovoltage, so a comparison of 60 kVp to 70 kVp was made. The ability to detect caries with a lower kVp setting, which provides a higher contrast effect, has been documented.<sup>24</sup> In the current study design, a detectable threshold thickness value of aluminum existed. The lowest 1-mm-thick step could not be identified when 70 kVp was used. When the 60-kVp setting was selected, neither the 2-mm-thick nor the 1-mm-thick aluminum step could be identified. This indicates that specimens with less radiographic density would be more difficult to detect with a lower kVp setting. These results are contrary to that expected if only the kVp was altered. However, the radiographic unit used has preset times associated with the selected kVp, which affects overall radiographic exposure.<sup>26</sup> It is accepted

that when objects low in radiographic density are imaged, decreasing the kVp will increase the likelihood of detecting them. Once the threshold detectable grey level value was exceeded for the lower kilovoltage value, the specimens demonstrated similar aluminum thickness equivalents. Variable responses of the digital dental radiographic system to detect radiation over the detector's surface have been reported.<sup>23</sup> It has been shown that, because of sensor inhomogeneity, there is a reduced ability to reflect changes in mass in the central parts of the sensing area. For this reason, 5 disks were placed on the PSP image plate, and values were recorded and averaged.<sup>22</sup>

Regarding the target distance chosen, a recent study confirmed that an FFD of 300 mm would provide results equivalent<sup>14</sup> to the ISO 4049 recommendation of 400 mm.<sup>25</sup> Maintaining an FFD ensures a uniform irradiation of the imaging plate.

This study was designed specifically to compare radiographic density val-

ues for some currently used cements only. It did not consider the effects of the soft tissues that would alter levels of radiographic density by absorption, which could allow some low density cements to become visible on an image when the soft tissue thicknesses are superimposed. The background effect of the titanium implant or abutment material may have an effect on the ability to radiographically detect excess implant cement overhangs. This was alluded to in a previous study<sup>13</sup> that suggested radiopaque luting agent detection was improved when specimens were observed against a nonradiopaque material, a contrast effect. Another limitation of the present study was that specimens were maintained in a set dry state to assess absolute radiodensity. The grey level values may be affected by moisture adsorption from or loss to the oral environment. Further in vivo studies are required to evaluate these effects.

## CONCLUSIONS

Within the limitations of this study, it was found that TempBond (zinc oxide with eugenol) demonstrated the highest grey level values for the cements tested. All cements containing zinc (TempBond, TempBond NE, Fleck's) could be detected radiographically in both 2-mm and 1-mm thicknesses. At both 60-kVp and 70-kVp settings, the 1-mm-thick zinc-containing cements produced similar aluminum equivalence values. The less radiodense materials with thicknesses of 1 mm, such as Dycal (calcium hydroxide), were not detected with the lower kVp setting. The RelyX Luting (glass ionomer cement), RelyX Unicem (self-adhesive resin cement), and Improv (resin cement) performed similarly in that they could be detected only when the thicker specimen of 2 mm was irradiated. None of the 3 previously mentioned cements could be detected at the 1-mm-thick level. Premier Implant Cement (resin cement) could not be detected at 2-mm or 1-mm thicknesses, or with 60-kVp or 70-kVp

settings. This in vitro comparison provides the restorative dentist the ability to gauge the radiographic character of the cement material used. It is desirable that the cement be as radiopaque as possible while demonstrating other required physical properties. For cements with low radiodensity, the manufacturers should perhaps reconsider formulations to improve this aspect.

## REFERENCES

1. De Rouck T, Collys K, Cosyn J. Single-tooth replacement in the anterior maxilla by means of immediate implantation and provisionalization: a review. *Int J Oral Maxillofac Implants* 2008;23:897-904.
2. Hebel KS, Gajjar R. Cement-retained versus screw-retained implant restorations: achieving optimal occlusion and esthetics in implant dentistry. *J Prosthet Dent* 1997;77:28-35.
3. Weber HP, Kim DM, Ng MW, Hwang JW, Fiorellini JP. Peri-implant soft-tissue health surrounding cement- and screw-retained implant restorations: a multi-center, 3-year prospective study. *Clin Oral Implants Res* 2006;17:375-9.
4. Pualetto N, Lahiffe BJ, Walton JN. Complications associated with excess cement around crowns on osseointegrated implants: a clinical report. *Int J Oral Maxillofac Implants* 1999;14:865-8.
5. Gapski R, Neugeboren N, Pomeranz AZ, Reissner MW. Endosseous implant failure influenced by crown cementation: a clinical case report. *Int J Oral Maxillofac Implants* 2008;23:943-6.
6. Thomas GW. The positive relationship between excess cement and peri-implant disease: a prospective clinical endoscopic study. *J Periodontol* 2009; 80:1388-92.
7. Dumbrigue HB, Abanomi AA, Cheng LL. Techniques to minimize excess luting agent in cement-retained implant restorations. *J Prosthet Dent* 2002;87:112-4.
8. Schwedhelm ER, Lepe X, Aw TC. A crown venting technique for the cementation of implant-supported crowns. *J Prosthet Dent* 2003;89:89-90.
9. Wadhvani CP, Piñeyro A. Technique for controlling the cement for an implant crown. *J Prosthet Dent* 2009;102:57-8.
10. O'Rourke B, Walls AW, Wassell RW. Radiographic detection of overhangs formed by resin composite luting agents. *J Dent* 1995;23:353-7.
11. Soares CJ, Santana FR, Fonseca RB, Martins LR, Neto FH. In vitro analysis of the radiodensity of indirect composites and ceramic inlay systems and its influence on the detection of cement overhangs. *Clin Oral Investig* 2007;11:331-6.
12. Fonseca RB, Branco CA, Soares PV, Corrêa-Sobrinho L, Haiteir-Neto F, Fernandes-Neto AJ, et al. Radiodensity of base, liner and luting dental materials. *Clin Oral Investig* 2006;10:114-8.

13. Devito KL, Ortega AI, Haiteir-Neto F. Radiopacity of calcium hydroxide cement compared with human tooth structure. *J Appl Oral Sci* 2004;12:290-3.
14. Gu S, Rasimick BJ, Deutsch AS, Musikant BL. Radiopacity of dental materials using a digital X-ray system. *Dent Mater* 2006;22:765-70.
15. Rosenstiel SF, Land MF, Crispin BJ. Dental luting agents: a review of the current literature. *J Prosthet Dent* 1998;80:280-301.
16. Michalakakis KX, Pissiotis AL, Hirayama H. Cement failure loads of 4 provisional luting agents used for the cementation of implant-supported fixed partial dentures. *Int J Oral Maxillofac Implants* 2000;15:545-9.
17. Sheets JL, Wilcox C, Wilwerding T. Cement selection for cement-retained crown technique with dental implants. *J Prosthodont* 2008;17:92-6.
18. Mansour A, Ercoli C, Graser G, Tallents R, Moss M. Comparative evaluation of casting retention using the ITI solid abutment with six cements. *Clin Oral Implants Res* 2002;13:343-8.
19. Pan YH, Ramp LC, Lin CK, Liu PR. Retention and leakage of implant-supported restorations luted with provisional cement: a pilot study. *J Oral Rehabil* 2007;34:206-12.
20. Fraga RC, Luca-Fraga LR, Pimenta LA. Physical properties of resinous cements: an in vitro study. *J Oral Rehabil* 2000;27:1064-7.
21. Agar JR, Cameron SM, Hughbanks JC, Parker MH. Cement removal from restorations luted to titanium abutments with simulated gingival margins. *J Prosthet Dent* 1997;78:43-7.
22. Begoña Ormaechea MB, Millstein P, Hirayama H. Tube angulation effect on radiographic analysis of the implant-abutment interface. *Int J Oral Maxillofac Implants* 1999;1:77-85.
23. Chen SK, Hollender L, Omnell KA. Detection of small differences in mass using a direct digital dental X-ray system. *Dentomaxillofac Radiol* 1997;26:63-6.
24. Svenson B, Gröndahl HG, Petersson A, Olving A. Accuracy of radiographic caries diagnosis at different kilovoltages and two film speeds. *Swed Dent J* 1985;9:37-43.
25. International Organization for Standardization. ISO 4049:2009. Dentistry -- polymer-based restorative materials. Geneva: ISO; 2009. Available at: <http://www.iso.ch/iso/en/prods-services/ISOstore/store.html>. Accessed September 16, 2009.
26. White SC, Pharoah MJ. Oral radiology, 6<sup>th</sup> ed: principles and interpretation. St. Louis: Elsevier; 2009. p. 59-60, 152-3.
27. American Dental Association. ADA/FDA guide to patient selection for dental radiographs. ADA: Chicago; 2004 Available at: <http://www.ada.org/prof/resources/topics/radiography.asp#radiograph>. Accessed September 9, 2009.

### Corresponding author:

Dr Chandur Wadhvani  
1200 116<sup>th</sup> Ave NE, Ste A  
Bellevue, WA 98004  
Fax: 425-462-1878  
E-mail: cpkw@u.washington.edu

Copyright © 2010 by the Editorial Council for  
*The Journal of Prosthetic Dentistry.*