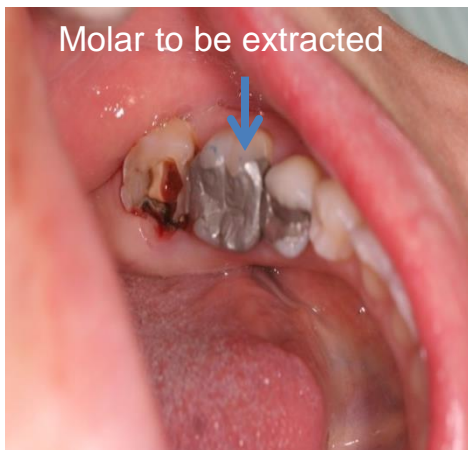

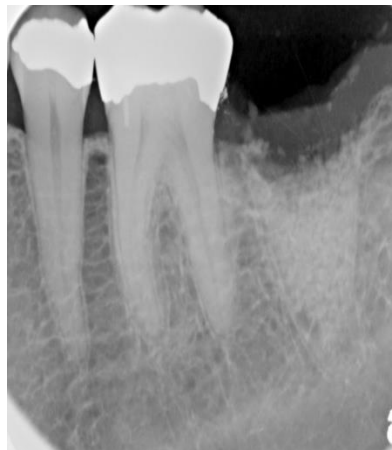# Stability of single tooth implant after autologous dentin grafting

**Case description:** Tooth #36 was extracted because of perforated root . The socket was grafted and during 5 month a permanent restoration on implant was accomplished.

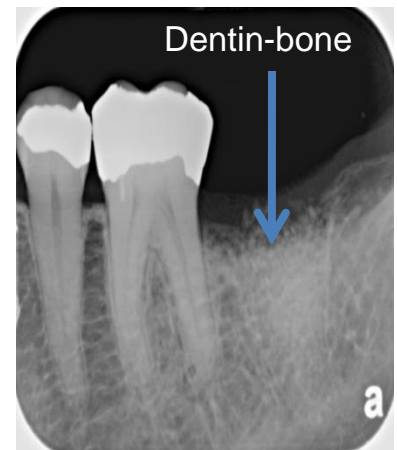
**Result:** Autologous dentin graft allows shorter healing period and high stability of implant.



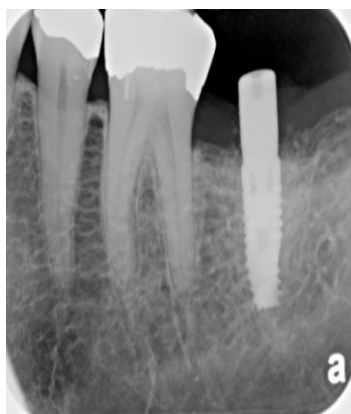
*October 2013*



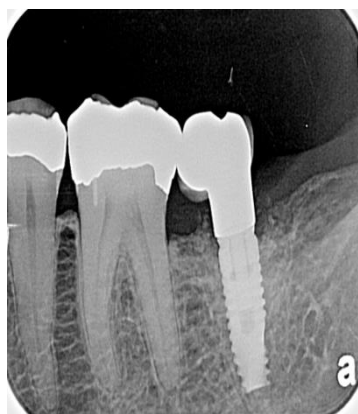
*October 2013 –  
extraction and graft*



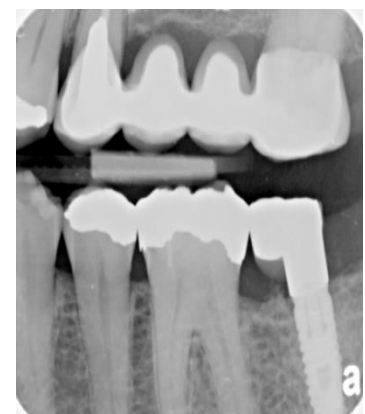*December 2013 –  
implant placement*



*January 2014*



*March 2014*



*July 2015*