

Treatment strategy for treating atrial-esophageal fistula: esophageal stenting or surgical repair?

A case report and literature review

Bing Zhou, MD^a, Xue-Jiang Cen, MD^b, Lin-Yan Qian, MD^b, Jie Pang, MD^b, Hai Zou, MD^{b,*}, Ya-Hui Ding, MD^{b,*}

Abstract

Introduction: Atrial-esophageal fistula (AEF) is a rare severe disease, which may be associated with radiofrequency catheter ablation (RFCA) of atrial fibrillation (AF) or intraoperative radiofrequency ablation of atrial fibrillation (IRAAF).

Clinical Findings: We reported a case of a 67-year-old man with AEF following RFCA of AF, who treated with esophageal stenting and surgical repair.

Outcomes: He was attacked by out-of-control sepsis and infectious shock after surgery and died.

Literature review: We analyzed 57 relevant articles about AEF from 2003 to 2015 by searching PubMed database. According to literatures, the most common symptoms were fever, rigor, sepsis, and neurologic symptoms. Chest computer tomography (CT) and contrast enhanced CT may be the reliable noninvasive diagnosis methods because of high sensitive for AEF.

Conclusion: Make a definition diagnosis in time with early primary surgical repair may save their lives. Conservative treatment or esophageal stenting alone may not be a better choice for AEF patients.

Abbreviations: AEF = atrial-esophageal fistula, AF = atrial fibrillation, CECT = contrast-enhanced computer tomography, CT = computer tomography, ECG = electrocardiogram, EGD = esophagogastroduodenoscopy, ET = exploratory thoracotomy, GI = gastrointestinal, hsCRP = high sensitivity C reactive protein, IRAAF = intraoperative radiofrequency ablation of atrial fibrillation, LA = left atrium, MRI = magnetic resonance imaging, NT-proBNP = N-terminal pro brain natriuretic peptide, RFCA = radiofrequency catheter ablation, WBC = white blood count.

Keywords: atrial fibrillation, atrial-esophageal fistula, catheter ablation, esophageal stenting, surgical repair

1. Introduction

Atrial-esophageal fistula (AEF) is a rare severe disease, which may be associated with radiofrequency catheter ablation (RFCA) of atrial fibrillation (AF) or intraoperative radiofrequency ablation of atrial fibrillation (IRAAF). We presented a case of a 67-year-old man with AEF following RFCA treated with esophageal

stenting and surgical repair, and then reviewed literatures about AEF to explore the appropriate treatment options.

2. Case presentation

A 67-year-old man, who had coronary heart disease, AF, and heart failure, was admitted because of dyspnea and rapid AF. The symptoms improved after treating by diuretics, milrinone, and nitrate. Then RFCA of AF was performed to perform wide area circumferential ablations to achieve pulmonary vein isolation using a 3.5 mm tip electrode on a D-curved thermocool catheter through Agilis sheath. The lesions were applied for 30 to 60 s with 30 to 30 W. The patient discharged from the hospital 3 days after the procedure.

But 18 days after the procedure, the patient was admitted to local hospital with complaint of chest discomfort and fever for 1 day. His manifestation was confusion, gazing upwards, mild limb seizures, and vomiting. His temperature was 41°C, white blood count (WBC) $5.2 \times 10^9/L$, and high sensitivity C reactive protein (hsCRP) 18.56 mg/L. Electrocardiogram (ECG) showed supraventricular tachycardia.

Then he presented to emergency department of our hospital after hypothermia therapy. At admission, physical examination revealed that his temperature was 37.9°C, blood pressure was 99/73 mm Hg, and pulse rate was 78 beats/min. ECG showed AF. The initial laboratory studies showed N-terminal pro brain natriuretic peptide (NT-proBNP) 1550.00 pg/mL, alanine aminotransferase 21 U/L, cardiac troponin I 3.95 μg/L, WBC $10.58 \times 10^9/L$, neutrophil 97.2%, hsCRP 26.0 mg/L, and fecal occult blood 3+. Cerebral and pulmonary computer tomography

Editor: Zhonghua Sun.

Co-first author: BZ and X-JC.

BZ, HZ, and Y-HD planned the article and contributed to data collection, discussing content, and writing and reviewing the article. X-JC, L-YQ, and JP participated in its design, study supervision, and helping to writing the article.

Informed patient consent was obtained for publication of this case report.

The authors have no funding and conflicts of interest to disclose.

^a Department of Cardiac Surgery, Zhejiang Provincial People's Hospital,

^b Department of Cardiology, Zhejiang Provincial People's Hospital, Hangzhou, China.

* Correspondence: Ya-Hui Ding and Hai Zou, Department of Cardiology, Zhejiang Provincial People's Hospital, Hangzhou 310000, China (e-mail: dyh@zjheart.com [Y-HD] and zjhaire1993@163.com [HZ]).

Copyright © 2016 the Author(s). Published by Wolters Kluwer Health, Inc. All rights reserved.

This is an open access article distributed under the terms of the Creative Commons Attribution-Non Commercial License 4.0 (CCBY-NC), where it is permissible to download, share, remix, transform, and buildup the work provided it is properly cited. The work cannot be used commercially without permission from the journal.

Medicine (2016) 95:43(e5134)

Received: 30 April 2016 / Received in final form: 3 August 2016 / Accepted: 23 September 2016

<http://dx.doi.org/10.1097/MD.0000000000005134>

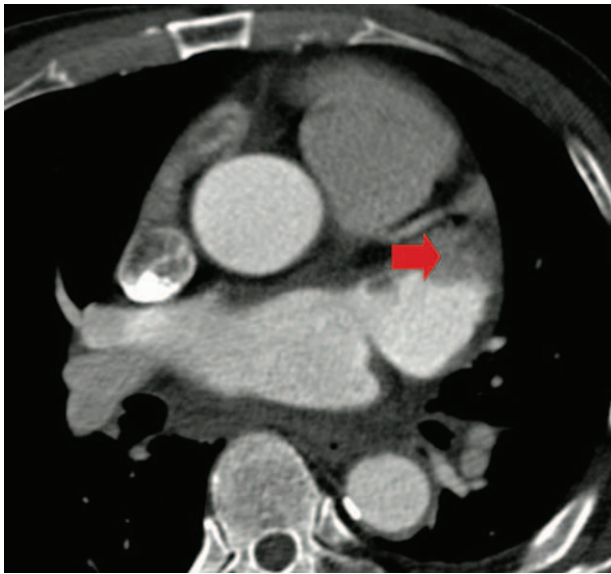


Figure 1. Contrast-enhanced computed tomography showed suspicious thrombus in left atrial appendage (indicated by red arrow).

(CT) did not reveal any abnormal findings. Contrast-enhanced CT (CECT) showed suspicious thrombus in left atrial appendage (Fig. 1).

Patient was asked to fast with gastrointestinal (GI) decompression, and used antibiotic, imipenem/cilastatin and linezolid, to control infections. He regained consciousness from the next day after admitting our institution, but he still had repeated epileptic seizures. Cerebral magnetic resonance imaging (MRI) was performed and showed lacuna infarctions (Fig. 2). Emergency esophagogastroduodenoscopy (EGD) showed a small and deep ulcer at 30 cm from incisors. The esophagus was stented with self-expanding, polyester-covered, length 100 mm, width 18 mm (Nanjing Micro-Tech, Nanjing, China) (Fig. 3). In the following days, WBC counts and hsCRP level decreased, epileptic seizures went away. But the symptom of acid reflux occurred from the 5th day after esophageal stenting when he ate fluid food. Temperature and WBC counts increased again from the 7th day. Cardiac CECT showed esophageal-mediastinum fistula with encapsulated effusion and pneumatosis behind left atrium (LA),

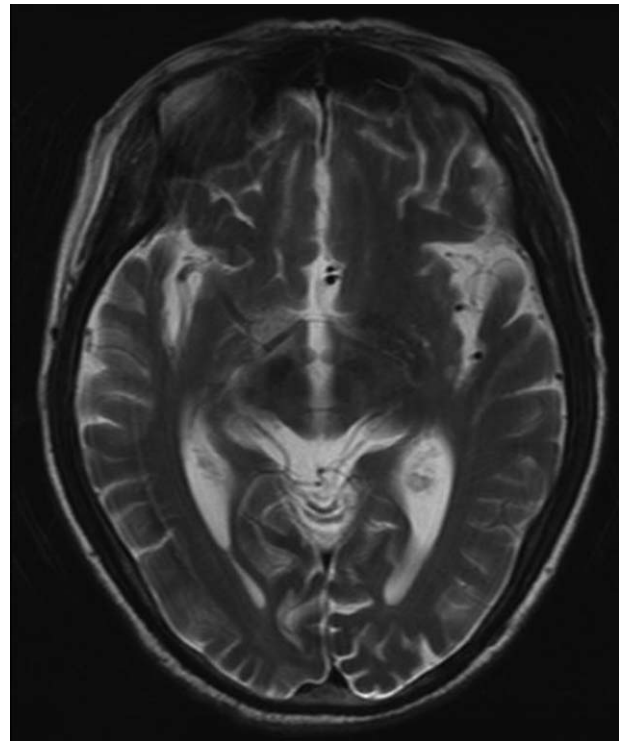


Figure 2. Cerebral magnetic resonance imaging showed lacuna infarctions.

and post wall of LA depression. Mediastinal abscess and AEF were considered and surgical repair was planned.

Right thoracotomy incision through the right 5th intercostal space was made under general anesthesia. During the surgery, we noticed the membranaceous and funicular adhesions between the right lung, diaphragm and mediastinum, white lamellar scars under azygos vein beside left atrial. After opening mediastinal pleura, tight adhesion between esophagus and pericardium was found and separated carefully, then a 6 mm diameter fistula in the anterior wall of esophagus was discovered (Fig. 4). Tight adhesion between LA and pericardium, combined with bleeding at the posterior wall of LA, was found during exploratory pericardiotomy. Rid-muscle flap pedicled with vessels was made to repair LA posterior wall and fistula between esophagus and LA

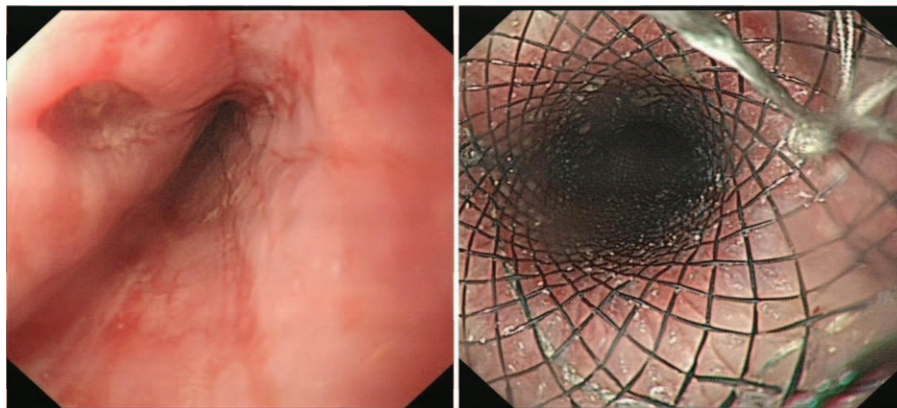


Figure 3. Emergency esophagogastroduodenoscopy showed a small and deep ulcer at 30 cm from incisors (left). The esophageal stent had been implanted (right).

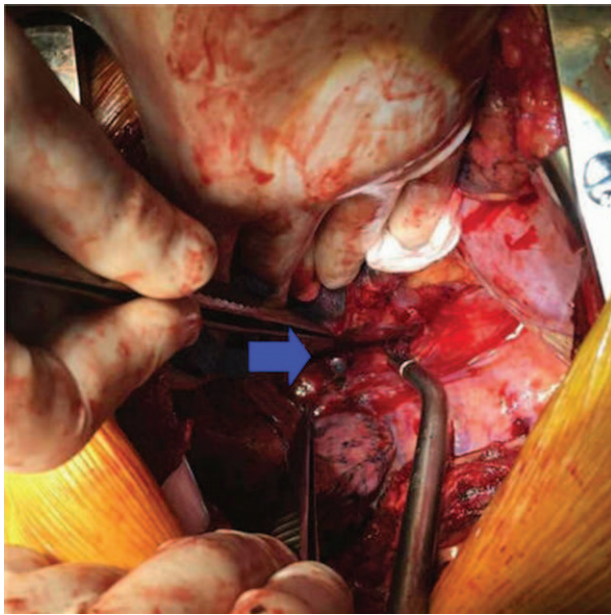


Figure 4. A 6 mm diameter fistula (indicated by blue arrow) in the anterior wall of esophagus.

(Fig. 5). Pleuroclysis using povidone iodine and nature saline was performed before sternal closure.

After surgery, the patient was transferred to intensive care unit, and then out-of-control sepsis and infectious shock, which showed repeated fever and chills, metabolic acidosis, hypotension, tachycardia and oliguria, attacked the patient, and caused his death.

3. Discussion

AEF, a rarely complication of RFCA of AF, was first reported in 2004.^[1] Some surveys revealed that the incidence was 0.03% to

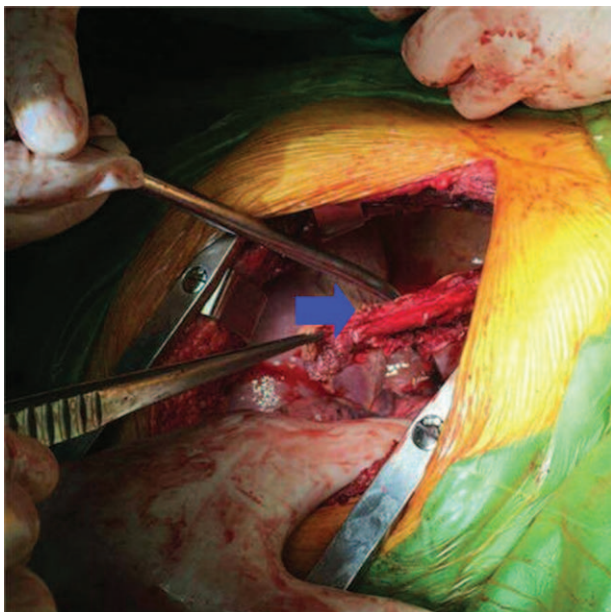


Figure 5. Rib-muscle flap pedicled with vessels (indicated by blue arrow) was used to repair LA posterior wall and fistula between esophagus and LA. LA= left atrium.

Table 1	
Characteristics of patients.	
Characteristics	Value
No. of cases, n	86
Male gender, n	60
Age (mean ± SD), y	56.3 ± 12.2
Procedure	
Catheter ablation, n	78
Surgical, n	8
Mean timing of presentation (range), d	24.8 (2–60)
Outcome (survived), n/n	36/86

SD = standard deviation.

0.04% in RFCA of AF and about 1% in IRAAF, and its mortality ranging was from 71% to 83%.^[2–4] As the number of RFCA of AF cases grows, more AEF cases could be found in recent years. It was considered that the ablation of the posterior wall of LA by the high temperature might be an important risk of AEF.^[5] Elevated esophageal temperatures during LA ablation may occur in more than 50% of patients.^[5,6]

Esophageal stenting and surgical repair are the commonest treatment for AEF. To date, we still did not know which one is the best treatment for AEF. So we searched PubMed database about AEF from 2003 to 2015. Fifty-seven relevant articles, including 86 AEF patients (60 males), were analyzed.^[1,6–61] Seventy-eight patients were secondary to RFCA of AF, and 8 patients were secondary to IRAAF. The incubation period of AEF symptoms was from 2 to 60 (average: 24.8) days. The mortality of the patients was 58.1% (Table 1).

The most common symptoms were fever, rigor, and sepsis. The symptoms of neurological symptoms, including hemiplegia and epilepsy, consciousness disorder, GI bleeding, chest pain, were relatively common. The other uncommon symptoms included: nausea and vomiting, dysphagia, dyspnea, cough, arrhythmia, headache, blindness, syncope, abdominal pain, and petechiae (Fig. 6).

Chest CT and CECT were the most common noninvasive diagnosis methods with high sensitive for AEF, which could show the air bubbles or vegetation at the site near the esophagus of LA. Sometimes mediastinum emphysema could be found. EGD was a

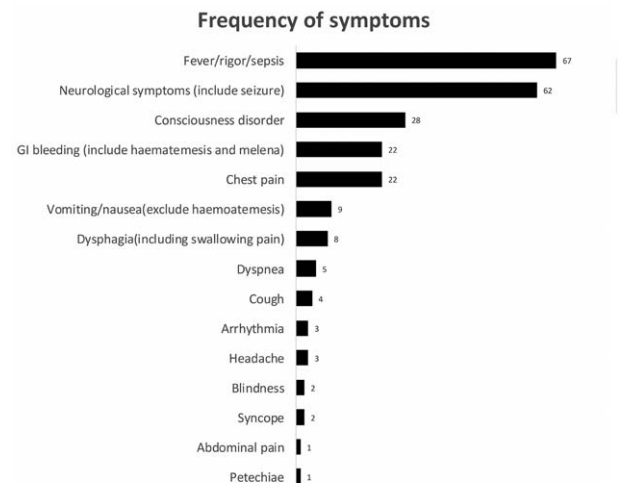


Figure 6. Frequency of symptoms at the time of hospitalization.

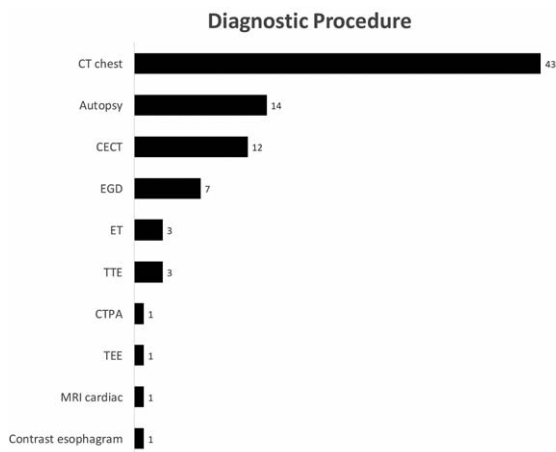


Figure 7. Diagnostic procedure at the time of hospitalization. CECT = contrast enhanced computed tomography, CTPA = computed tomography pulmonary angiogram, EGD = esophagogastroduodenoscopy, ET = exploratory thoracotomy, TEE = transesophageal echocardiography, TTE = transthoracic echocardiography.

common diagnostic way too. In some cases, AEF was only diagnosed during autopsy or exploratory thoracotomy. Transthoracic echocardiography, transesophageal echocardiography, cardiac MRI, and contrast esophagram could discover AEF (Fig. 7). Abnormal cerebral CT findings, such as cerebral air embolism and multifocal cerebral ischemia, revealed in most of patient on admission.

Hemorrhage from AEF, sepsis, air embolism, and cerebrovascular accidents are the major reasons for a fatal outcome.^[2,6,9,12,23,57] Esophageal stenting and surgical repair were the major therapies of AEF. Different therapeutic strategy might influence outcome of patients. Twenty-eight patients without esophageal stenting or surgical repair had higher mortality, only 1 patient who performed endoscopic ligation survived. Ten patients who treated with esophageal stenting all died. But relatively, surgical repair decreased the mortality of the patients significantly, only 12 patients died in 43 patients who only performed surgical. Three patients implanted esophageal stenting after performing emergency atrial wall repair with thoracotomy, 2 patients survived. Two patients, who received esophageal stenting and subsequently performed surgical, were all survived (Table 2).

It is known to all that AEF is a life-threatening complication of ablation of AF. An appropriate treatment is the key to reduce mortality of patients with AEF. According to the literature review of AEF, we found that conservative treatment or esophageal stenting alone seemed to be a poor clinical outcomes, and surgical repair combined with or without esophageal stenting may be the preferred option for the patients. Early surgical treatment have lower mortality than delayed strategy.^[8,19,23,26,37] Though there were many disputes about the opportunity to put esophageal stent, stenting alone was not recommended for treating AEF.^[26,37] The clinical outcomes of combination therapy of esophageal stenting and surgical repair were not clear because of few cases.

In our case, the patient underwent early esophageal stenting with temporary improvement of the symptoms in the first few days. But the conditions of the patient were worse, and eventually caused death despite surgical repair was performed. Early

Table 2

Treatments and outcomes.

Intervention for AEF		Death	Survived	No sequels
Stent (+)	Surgical (-)	10	0	
Stent (-)	Surgical (+)	12	30	1
Stent (-)	Surgical (-)	27	1*	
Stent (+)	Surgical (+) [†]	1	2	
Stent (+)	Surgical (+) [‡]	0	2	

AEF = atrial-esophageal fistula.
 * Underwent endoscopic ligation.
 † Primary surgical repair.
 ‡ Primary esophageal stenting.

resuming oral intake and delayed surgical intervention may be the important factors of relapse.

4. Conclusion

Chest CT and CECT are high sensitive noninvasive diagnostic methods for AEF. Make a definition diagnosis in time with early primary surgical repair may save their lives. Conservative treatment or esophageal stenting alone may not be a better choice for AEF patients.

References

- [1] Pappone C, Oral H, Santinelli V, et al. Atrio-esophageal fistula as a complication of percutaneous transcatheter ablation of atrial fibrillation. *Circulation* 2004;109:2724–6.
- [2] Ghia KK, Chugh A, Good E, et al. A nationwide survey on the prevalence of atrioesophageal fistula after left atrial radiofrequency catheter ablation. *J Interv Card Electrophysiol* 2009;24:33–6.
- [3] Cappato R, Calkins H, Chen SA, et al. Updated worldwide survey on the methods, efficacy, and safety of catheter ablation for human atrial fibrillation. *Circ Arrhythm Electrophysiol* 2010;3:32–8.
- [4] Doll N, Borger MA, Fabricius A, et al. Esophageal perforation during left atrial radiofrequency ablation: is the risk too high? *J Thorac Cardiovasc Surg* 2003;125:836–42.
- [5] Liu E, Shehata M, Liu T, et al. Prevention of esophageal thermal injury during radiofrequency ablation for atrial fibrillation. *J Interv Card Electrophysiol* 2012;35:35–44.
- [6] French KF, Garcia C, Wold JJ, et al. Cerebral air emboli with atrial-esophageal fistula following atrial fibrillation ablation: a case report and review. *Neurohospitalist* 2011;1:128–32.
- [7] Sonmez B, Demirsoy E, Yagan N, et al. A fatal complication due to radiofrequency ablation for atrial fibrillation: atrio-esophageal fistula. *Ann Thorac Surg* 2003;76:281–3.
- [8] Podgaetz E, Deschamps C. Esophageal complications of catheter ablation for atrial fibrillation: a case report. *J Thorac Cardiovasc Surg* 2013;145:e9–13.
- [9] Ben-David K, Rosenthal M, Chauhan SS. A novel strategy for the management of acute hemorrhage from an atrio-esophageal fistula after atrial ablation. *Am Surg* 2012;78:E286–7.
- [10] Rajakulasingam R, Francis R, Ghuran A. A rare complication following radiofrequency ablation. *BMJ Case Rep* 2013;2013:
- [11] Gunes MF, Gokoglan Y, DI Biase L, et al. Ablating the posterior heart: cardioesophageal fistula complicating radiofrequency ablation in the coronary sinus. *J Cardiovasc Electrophysiol* 2015;26:1376–8.
- [12] Gallo de Moraes A, Patel PA, Mahal E, et al. Acute fever and seizure in a patient with recent atrial fibrillation ablation. *Heart Lung* 2015;44:314–6.
- [13] Danon A, Shurrab M, Nair KM, et al. Atrial fibrillation ablation using remote magnetic navigation and the risk of atrial-esophageal fistula: international multicenter experience. *J Interv Card Electrophysiol* 2015;43:169–74.
- [14] Stockigt F, Schrickel JW, Andrie R, et al. Atrioesophageal fistula after cryoballoon pulmonary vein isolation. *J Cardiovasc Electrophysiol* 2012;23:1254–7.

- [15] Tancevski I, Hintringer F, Stuehlinger M, et al. Atrioesophageal fistula after percutaneous transcatheter ablation of atrial fibrillation. *Circulation* 2012;125:966.
- [16] Tan C, Coffey A. Atrioesophageal fistula after surgical unipolar radiofrequency atrial ablation for atrial fibrillation. *Ann Thorac Surg* 2013;95:e61–2.
- [17] Rajapaksha WR, Cunningham KS, Rose TH. A fatal case of atrioesophageal fistula following radiofrequency ablation of left atrium and pulmonary veins for atrial fibrillation. *Cardiovasc Pathol* 2014; 23:238–40.
- [18] Lim HW, Cogert GA, Cameron CS, et al. Atrioesophageal fistula during cryoballoon ablation for atrial fibrillation. *J Cardiovasc Electrophysiol* 2014;25:208–13.
- [19] Nair GM, Nery PB, Redpath CJ, et al. Atrioesophageal fistula in the era of atrial fibrillation ablation: a review. *Can J Cardiol* 2014;30:388–95.
- [20] Vilades Medel D, Marti-Almor J, Montiel Serrano J, et al. Atrioesophageal fistula secondary to pulmonary vein cryoablation. *Eur Heart J Cardiovasc Imaging* 2014;15:116.
- [21] Moss CE, Fernandez-Caballero S, Walker D. Atrio-oesophageal fistula after transcatheter radiofrequency ablation. *BMJ Case Rep* 2015;2015:2015.
- [22] Zini A, Carpegiani P, Pinelli G, et al. Brain air embolism secondary to atrial-esophageal fistula. *Arch Neurol* 2012;69:785.
- [23] Cummings JE, Schweikert RA, Saliba WI, et al. Brief communication: atrial-esophageal fistulas after radiofrequency ablation. *Ann Intern Med* 2006;144:572–4.
- [24] Aryana A, Arthur A, O'Neill PG, et al. Catastrophic manifestations of air embolism in a patient with atrioesophageal fistula following minimally invasive surgical ablation of atrial fibrillation. *J Cardiovasc Electrophysiol* 2013;24:933–4.
- [25] Lempel JK, Jozwik B, Manfredi C, et al. Cerebral air embolism: a result of atrioesophageal fistula. *AJNR Am J Neuroradiol* 2012;33:E40–1.
- [26] Singh SM, d'Avila A, Singh SK, et al. Clinical outcomes after repair of left atrial esophageal fistulas occurring after atrial fibrillation ablation procedures. *Heart Rhythm* 2013;10:1591–7.
- [27] Shim CY, Lee SY, Pak HN. Coronary air embolism associated with atrioesophageal fistula after ablation of atrial fibrillation. *Can J Cardiol* 2013;29:1329e17–9.
- [28] Zellerhoff S, Lenze F, Schulz R, et al. Fatal course of esophageal stenting of an atrioesophageal fistula after atrial fibrillation ablation. *Heart Rhythm* 2011;8:624–6.
- [29] Koa-Wing M, Jamil-Copley S, Ariff B, et al. Haemorrhagic cerebral air embolism from an atrio-oesophageal fistula following atrial fibrillation ablation. *Perfusion* 2015;30:484–6.
- [30] Wang MH, Razack A, Ray M. Hematemesis in a patient presenting with right-sided weakness and recent percutaneous catheter radiofrequency ablation for atrial fibrillation. *Gastroenterology* 2014;147: 35–6.
- [31] Hirji SA, Haney JC, Welsby I, et al. Hyperbaric oxygen therapy for treatment of neurologic sequela after atrioesophageal fistula. *Ann Thorac Surg* 2015;99:681–2.
- [32] Velotta JB, Vasquez CR, Bolman RM, et al. Left atrial-esophageal fistula repair after radiofrequency catheter ablation for atrial fibrillation. *Thorac Cardiovasc Surg Rep* 2013;2:13–5.
- [33] Garala K, Gunarathne A, Jarvis M, et al. Left atrial-oesophageal fistula: a very rare, potentially fatal complication of radiofrequency ablation for atrial fibrillation. *BMJ Case Rep* 2013;2013:2013.
- [34] Khandhar S, Nitzschke S, Ad N. Left atrioesophageal fistula following catheter ablation for atrial fibrillation: off-bypass, primary repair using an extrapericardial approach. *J Thorac Cardiovasc Surg* 2010;139: 507–9.
- [35] Arkuszewski P, Barzdo M, Ostrowski S, et al. Left atrio-esophageal fistula of a possibly iatrogenic aetiology. *Forensic Sci Int* 2015;252:e1–5.
- [36] Purerfellner H, Stollberger C, Finsterer J. Meningo-encephalitis as initial manifestation of a fatal atrio-oesophageal fistula after atrial fibrillation ablation. *Acta Cardiol* 2011;66:555–7.
- [37] Mohanty S, Santangeli P, Mohanty P, et al. Outcomes of atrioesophageal fistula following catheter ablation of atrial fibrillation treated with surgical repair versus esophageal stenting. *J Cardiovasc Electrophysiol* 2014;25:579–84.
- [38] Vassileva CM, Shawgo T, Shabosky J, et al. Repair of left atrial-esophageal fistula following percutaneous radiofrequency ablation for atrial fibrillation. *J Card Surg* 2011;26:556–8.
- [39] Rivera GA, David IB, Anand RG. Successful atrioesophageal fistula repair after atrial fibrillation ablation. *J Am Coll Cardiol* 2013;61:1204.
- [40] Shim HB, Kim C, Kim HK, et al. Successful management of atrioesophageal fistula after cardiac radiofrequency catheter ablation. *Korean J Thorac Cardiovasc Surg* 2013;46:142–5.
- [41] Shiraishi M, Morita H, Muramatsu K, et al. Successful non-operative management of left atrioesophageal fistula following catheter ablation. *Surg Today* 2014;44:1565–8.
- [42] Haggerty KA, George TJ, Arnaoutakis GJ, et al. Successful repair of an atrioesophageal fistula after catheter ablation for atrial fibrillation. *Ann Thorac Surg* 2012;93:313–5.
- [43] Cazavet A, Muscari F, Marachet MA, et al. Successful surgery for atrioesophageal fistula caused by transcatheter ablation of atrial fibrillation. *J Thorac Cardiovasc Surg* 2010;140:e43–5.
- [44] St Julien J, Putnam JBJr, Nesbitt JC, et al. Successful treatment of atrioesophageal fistula by cervical esophageal ligation and decompression. *Ann Thorac Surg* 2011;91:e85–6.
- [45] Hartman AR, Glassman L, Katz S, et al. Surgical repair of a left atrial-esophageal fistula after radiofrequency catheter ablation for atrial fibrillation. *Ann Thorac Surg* 2012;94:e91–3.
- [46] Khehra R, Agrawal S, Aoun E, et al. Unusual cause of upper gastrointestinal bleed, when OGD could be fatal. *BMJ Case Rep* 2015;2015:2015.
- [47] Wilson BD, Morshedzadeh JH. Atrioesophageal fistula and pneumocephalus after pulmonary vein isolation. *Eur Heart J Cardiovasc Imaging* 2015;16:819.
- [48] Kanth P, Fang J. Cerebral air embolism: a complication of a bleeding atrioesophageal fistula. *Clin Gastroenterol Hepatol* 2012;10:A22.
- [49] Scanavacca MI, D'Avila A, Parga J, et al. Left atrial-esophageal fistula following radiofrequency catheter ablation of atrial fibrillation. *J Cardiovasc Electrophysiol* 2004;15:960–2.
- [50] Zirlik A, Nordt TK. Massive air embolism after Maze. *Heart* 2005;91: 736.
- [51] Schley P, Gulker H, Horlitz M. Atrio-oesophageal fistula following circumferential pulmonary vein ablation: verification of diagnosis with multislice computed tomography. *Europace* 2006;8:189–90.
- [52] Preis O, Digumarthy SR, Wright CD, et al. Atrioesophageal fistula after catheter pulmonary venous ablation for atrial fibrillation: imaging features. *J Thorac Imaging* 2007;22:283–5.
- [53] Malamis AP, Kirshenbaum KJ, Nadimpalli S. CT radiographic findings: atrio-esophageal fistula after transcatheter percutaneous ablation of atrial fibrillation. *J Thorac Imaging* 2007;22:188–91.
- [54] D'Avila A, Ptaszek LM, Yu PB, et al. Images in cardiovascular medicine. Left atrial-esophageal fistula after pulmonary vein isolation: a cautionary tale. *Circulation* 2007;115:e432–3.
- [55] Borchert B, Lawrenz T, Hansky B, et al. Lethal atrioesophageal fistula after pulmonary vein isolation using high-intensity focused ultrasound (HIFU). *Heart Rhythm* 2008;5:145–8.
- [56] Hazell W, Heaven D, Kazemi A, et al. Atrio-oesophageal fistula: an emergent complication of radiofrequency ablation. *Emerg Med Australas* 2009;21:329–32.
- [57] Baker MJ, Panchal PC, Allenby PA. Life-threatening GI hemorrhage caused by atrioesophageal fistula: a rare complication after catheter ablation for atrial fibrillation. *Gastrointest Endosc* 2010;72:887–9.
- [58] Gilcrease GW, Stein JB. A delayed case of fatal atrioesophageal fistula following radiofrequency ablation for atrial fibrillation. *J Cardiovasc Electrophysiol* 2010;21:708–11.
- [59] Siegel MO, Parenti DM, Simon GL. Atrial-esophageal fistula after atrial radiofrequency catheter ablation. *Clin Infect Dis* 2010;51:73–6.
- [60] Neven K, Schmidt B, Metzner A, et al. Fatal end of a safety algorithm for pulmonary vein isolation with use of high-intensity focused ultrasound. *Circ Arrhythm Electrophysiol* 2010;3:260–5.
- [61] Dixit S, Gerstenfeld EP, Ratcliffe SJ, et al. Single procedure efficacy of isolating all versus arrhythmogenic pulmonary veins on long-term control of atrial fibrillation: a prospective randomized study. *Heart Rhythm* 2008;5:174–81.