


Movement of the Esophagus During Left Atrial Catheter Ablation for Atrial Fibrillation

[Eric Good](#), DO, [Hakan Oral](#), MD (FACC) , [Kristina Lemola](#), MD, [Jihn Han](#), MD, [Kamala Tamirisa](#), MD, [Petar Igic](#), MD, [Darryl Elmouchi](#), MD, [David Tschopp](#), MD, [Scott Reich](#), MD, [Aman Chugh](#), MD, [Frank Bogun](#), MD (FACC), [Frank Pelosi Jr](#), MD (FACC), [Fred Morady](#), MD (FACC)

Received 2 April 2005; received in revised form 5 July 2005; accepted 1 August 2005.
published online 08 November 2005.

Movement of the Esophagus During Left Atrial Catheter Ablation for Atrial Fibrillation

Eric Good, Hakan Oral, Kristina Lemola, Jihn Han, Kamala Tamirisa, Petar Igic, Darryl Elmouchi, David Tschopp, Scott Reich, Aman Chugh, Frank Bogun, Frank Pelosi, Jr, Fred Morady

In 51 patients with atrial fibrillation, the movement of the esophagus was assessed by digital cine-fluoroscopy after ingestion of barium paste before and after a left atrial catheter ablation procedure. In 67% of the patients, the esophagus moved along the posterior left atrium by ≥ 2 cm, and in 4% there was a ≥ 4 -cm shift. The width of the esophagus also changed throughout the procedure by 5 ± 7 mm (range = 0 to 36 mm). Because there of movement of the esophagus in a majority of patients during left atrial ablation, real-time imaging of the esophagus is necessary to avoid inadvertent applications of radiofrequency energy close to the esophagus.

Objectives

The aim of this study was to describe the extent of esophageal mobility that occurs during catheter ablation for atrial fibrillation under conscious sedation.

Background

Ablation along the posterior left atrium may cause an atrioesophageal fistula. One strategy for avoiding this risk is to not deliver radiofrequency energy at sites in contact with the esophagus.

Methods

In 51 consecutive patients with atrial fibrillation who underwent left atrial ablation under conscious sedation, digital cine-fluoroscopic imaging of the esophagus was performed in two views after ingestion of barium paste at the beginning and end of the ablation

procedure. Movement of the esophagus was determined at the superior, mid-, and inferior parts of the posterior left atrium in reference to the spine.

Results

Mean esophageal movement was 2.0 ± 0.8 cm (range = 0.3 to 3.8 cm) at the superior, 1.7 ± 0.8 cm (range = 0.1 to 3.5 cm) at the mid-, and 2.1 ± 1.2 cm (range = 0.1 to 4.5 cm) at the inferior levels. In 67% of the 51 patients, the esophagus shifted by ≥ 2 cm, and in 4% there was ≥ 4 cm of lateral movement. The mean change in esophageal luminal width was 5 ± 7 mm (range = 0 to 36 mm) at the superior, 5 ± 7 mm (range = 0 to 32 mm) at the mid-, and 6 ± 7 mm (range = 0 to 21 mm) at the inferior levels of the posterior left atrium.

Conclusions


The esophagus often is mobile and shifts sideways by ≥ 2 cm in a majority of patients undergoing catheter ablation for atrial fibrillation under conscious sedation. Therefore, real-time imaging of the esophagus may be helpful in reducing the risk of esophageal injury during radiofrequency ablation along the posterior left atrium.

Abbreviations and Acronyms: [AF](#), [atrial fibrillation](#) , [CS](#), [coronary sinus catheter](#) , [Eso](#), [esophagus](#)

Article Outline

Atrioesophageal fistula can develop as a result of thermal injury to the esophagus (Eso) after intraoperative ([1](#), [2](#), [3](#)) or percutaneous ([4](#), [5](#)) radiofrequency ablation along the posterior left atrium. One strategy for avoiding esophageal injury is to not deliver radiofrequency energy at left atrial sites that are in contact with the Eso. Static imaging of the Eso has demonstrated that the Eso has a variable course relative to the left atrium ([6](#)). However, because the Eso is a mobile structure ([6](#)), static imaging of the Eso may be an unreliable guide to the position of the Eso during an ablation procedure. This may be particularly true for procedures performed under conscious sedation, when esophageal peristalsis is likely to occur. The purpose of this study was to describe the extent of esophageal mobility that occurs in the course of left atrial ablation procedures performed under conscious sedation in patients with atrial fibrillation (AF).

Methods

 [return to article outline](#)

Study subjects

The subjects of this study were 51 consecutive patients who underwent a left atrial ablation procedure for AF. Their mean age was 56 ± 8 years. There were 42 men and 9 women. Atrial fibrillation was paroxysmal in 26 patients and chronic in 25, and had been

first documented 5 ± 5 years before referral. The mean left atrial diameter and left ventricular ejection fraction were 42 ± 8 mm and 0.56 ± 0.08 , respectively. Structural heart disease was present in seven patients, coronary artery disease in five, valvular heart disease in three, and a nonischemic cardiomyopathy in two.

Left atrial ablation procedure

The ablation procedures were performed in the fasting state. All patients provided informed written consent. Light conscious sedation was achieved with midazolam until the first barium swallow. After the barium swallow, both midazolam and fentanyl were administered to maintain conscious sedation. A quadripolar catheter (EP Technologies, Sunnyvale, California) was positioned within the coronary sinus through a femoral vein and was used for atrial pacing. After transeptal catheterization, systemic anticoagulation was achieved with intravenous heparin to maintain an activated clotting time of 300 to 350 s. Mapping and ablation were performed with a temperature-controlled, 8-mm-tip, quadripolar electrode catheter (Navistar, Biosense-Webster, Diamond Bar, California). Bipolar electrograms were recorded at a 30 to 500 Hz (EP Med Systems, West Berlin, New Jersey).

Left atrial ablation was performed under the guidance of a three-dimensional electroanatomical mapping system (CARTO, Biosense-Webster). Briefly, ablation was performed to target left atrial sites where fractionated electrograms or relatively short cycle lengths were recorded. Radiofrequency energy was delivered at a target temperature of 50°C and maximum power output of 70 W for 10 to 40 s at each target site. The end point of ablation was termination and noninducibility of AF ([7](#)).

All patients were observed overnight and treated with intravenous heparin. They were discharged home the day after ablation and treated with low-molecular-weight heparin for five days and warfarin for at least three months.

Study protocol

After construction of the left atrial geometry on the electroanatomical mapping system, patients were asked to swallow 5 ml of barium paste (E-Z-Paste, E-Z-EM Canada Inc., Westbury, New York), which was injected into the mouth with a syringe. Digital cine-fluoroscopic images were recorded during the barium swallow in anteroposterior and left-anterior-oblique 40° projections for >15 s. The position of the Eso was also marked on the virtual left atrial shell created with the electroanatomical mapping system. Radiofrequency energy was not delivered on the posterior left atrium within 5 mm of the esophageal border.

In most patients, there was residual barium staining of the Eso, and cine-fluoroscopic images were again acquired whenever movement of the Eso was noted or at the conclusion of left atrial ablation, whichever came first. An additional dose of barium paste was administered before acquisition of the final cine-fluoroscopic images. There were no instances of aspiration related to barium administration.


Measurements

All cine-fluoroscopic images were analyzed using software that enabled measurements with digital calipers (ProSolve, Bedford, United Kingdom). All measurements were made in two projections in reference to the spine. Measurements were made from the lateral and medial luminal borders of the Eso perpendicularly to the lateral border of the vertebral body at three levels: 1) superiorly, at the intersection of the Eso and the left atrial roof in the anteroposterior projection; 2) inferiorly, at the intersection of the Eso with the mitral annulus as identified by the coronary sinus catheter (CS); and 3) at a mid-level, halfway in between the superior and inferior measurements.

The width of the Eso was measured at the same three levels. Because the esophageal width may change, movement of the Eso was quantitated by noting the difference in distance between the lateral border of the vertebral column to the center point of the Eso before and after ablation. The change in position of the Eso was measured at three left atrial levels. The change in esophageal width was calculated at three levels in two projections before and after ablation. To account for magnification errors between the pre- and post-ablation images, all measurements were corrected based on the length of the electrodes of the quadripolar CS and the width of the vertebral bodies.

All measurement were made off-line by two investigators (E.G. and K.L.). The intra- and interobserver variabilities in the measurements of esophageal movement were $3 \pm 1\%$ and $3 \pm 1\%$, respectively. Continuous variables are expressed as mean values \pm SD.

Results

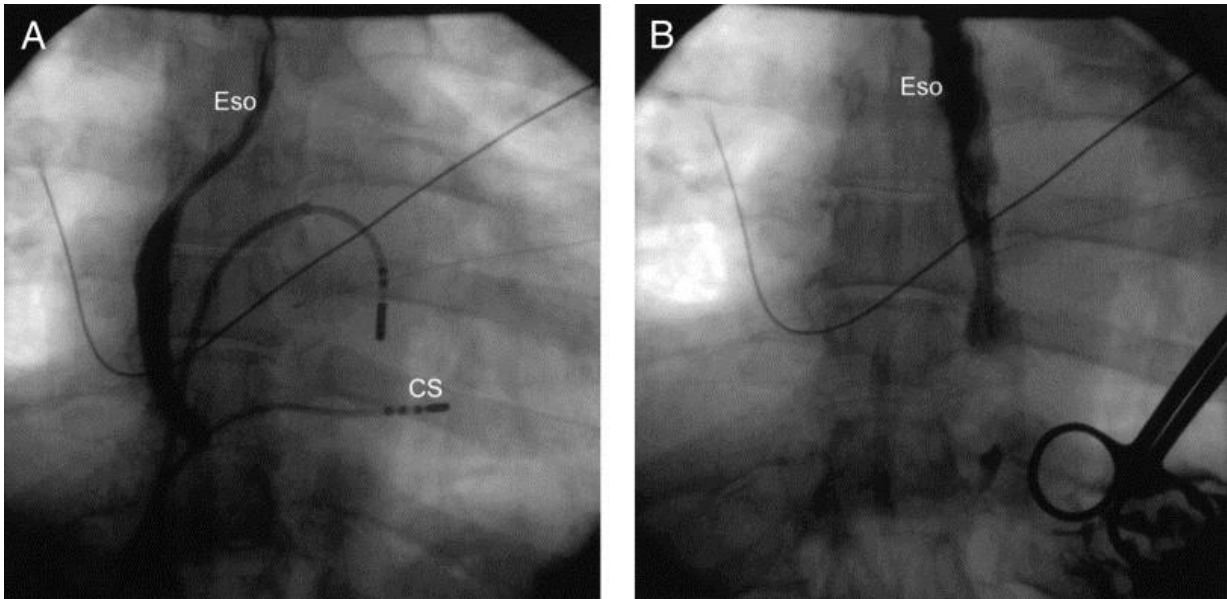
 [return to article outline](#)

Movement of the Eso

The mean interval between the pre- and post-ablation images of the Eso was 151 ± 41 min. The mean lateral movement of the Eso was 2.0 ± 0.8 cm (range = 0.3 to 3.8 cm, median = 2.0 cm) at the superior, 1.7 ± 0.8 cm (range = 0.1 to 3.5 cm, median = 1.6 cm) at the mid-, and 2.1 ± 1.2 cm (range = 0 to 4.5 cm, median = 2.1 cm) at the inferior levels of the left atrium ([Fig. 1](#)). The direction of esophageal migration was toward the right of the patient's spine in 21 (41%) and toward the left in 30 (59%) patients. In 26 patients (51%), the direction of lateral esophageal migration was the concordant at all levels.

Figure 1. Esophageal migration. The lumen of the esophagus (Eso) is visualized with barium paste. The position of the Eso before (**A**) and after (**B**) ablation is shown in the anteroposterior projection. In **A**, a left atrial mapping/ablation catheter and a quadripolar coronary sinus catheter (CS) are also shown.

Fig. 1



Overall, the Eso shifted by ≥ 1 cm in 49 patients (96%), by ≥ 2 cm in 34 patients (67%), and by ≥ 4 cm in 2 patients (4%).

The mean of the total dose of barium swallowed during the procedure was similar among patients who had < 2 cm of esophageal movement, 6.4 ± 2.3 ml, and who had ≥ 2 cm of esophageal movement, 7.3 ± 3.3 ml ($p = 0.3$).

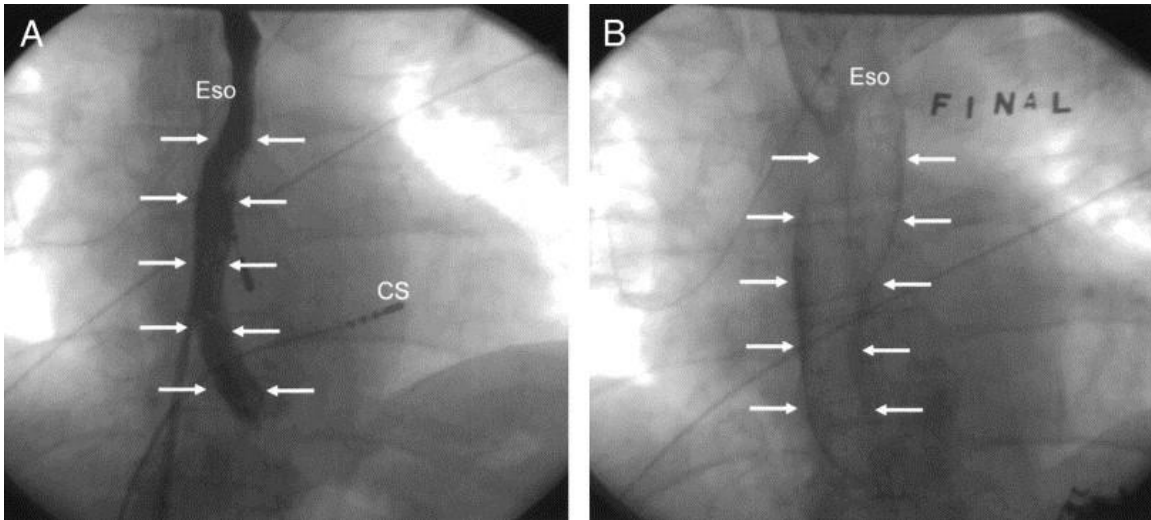
There was no significant difference in the time interval between the pre- and post-ablation images among patients who had < 2 cm (143 ± 36 min) and who had ≥ 2 cm of esophageal movement (155 ± 43 min, $p = 0.4$).

Esophageal width

Before ablation, the mean width of the esophageal lumen was 10 ± 5 mm at the superior level, 10 ± 5 mm at the mid-level, and 11 ± 5 mm at the inferior level. The minimum and maximum esophageal luminal diameter at any level was 0.4 mm and 42 mm, respectively. The mean change in esophageal width during the procedure was 5 ± 7 mm at the superior level, 5 ± 8 mm at the mid-level, and 6 ± 7 mm at the inferior level. Among the 51 patients, the esophageal width increased by ≥ 1 cm in 18 patients (35%) and by ≥ 2 cm in 2 patients (4%) ([Fig. 2](#)).

Figure 2. Change in esophageal luminal diameter. There was a marked difference in esophageal diameter before (A) and after (B) the ablation procedure in the anteroposterior projection. The borders of the esophageal lumen are marked with **arrows**. CS = coronary sinus catheter; Eso = esophagus.

Fig. 2

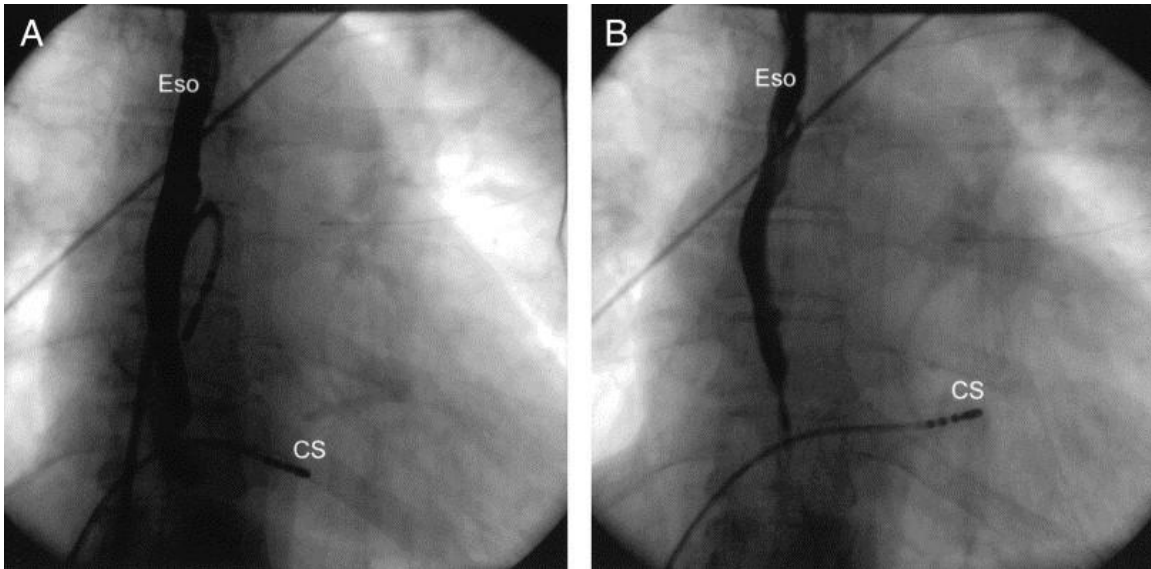


Overlap between the initial and follow-up esophageal position on the posterior left atrium

Among the 51 patients, the position of the Eso at the end of the ablation procedure was >5 mm outside the initial esophageal position on the posterior left atrial wall at ≥ 1 segment in 40 patients (78%). In the remaining 11 patients (22%), there was no appreciable change (>5 mm) in esophageal position before and after the ablation procedure ([Fig. 3](#)).

Figure 3. Visualization of the esophagus (Eso) in the anteroposterior projection. The position of the Eso was very similar before (A) and after (B) the ablation procedure. CS = coronary sinus catheter.

Fig. 3



Discussion

Main findings

This real-time cine-fluoroscopic study of the Eso demonstrates that the Eso often shifts its position relative to the left atrium in the course of an ablation procedure for AF. A medial or lateral shift of ≥ 2 cm was observed in two-thirds of patients over a mean time span of approximately 2.5 h. The width of the Eso also was dynamic, changing ≥ 1 cm in 35% of the patients. In 78% of the patients, changes in location and width of the Eso resulted in a post-ablation contact area with the posterior left atrium that did not overlap with the baseline contact area.

These findings demonstrate that a static image of the Eso obtained either before or during an ablation procedure is very unlikely to provide an accurate indication of the position of the Eso during an ablation procedure.

Esophageal migration

The Eso does not have a serosal layer and is fixed in the mediastinum primarily in the pharynx and the gastroesophageal junction. Its position within the mediastinum is dynamic, with its mobility being caused by peristalsis.

It could be argued that peristalsis and esophageal movement were amplified in the patients in this study by the oral administration of barium. However, under conscious sedation with a preserved gag reflex, patients continue to swallow their own saliva. Furthermore, there was no significant difference in the amount of barium swallowed

among patients who did and did not have marked esophageal movement. Therefore, it is unlikely that barium ingestion alone was responsible for movement of the Eso.

It is possible that deep sedation or general anesthesia is associated with less movement of the Eso than when conscious sedation is used. Furthermore, if the Eso is instrumented with a semi-rigid probe, this may inhibit sideways shifting of the Eso. Therefore, it should be noted that the results of this study may not be applicable to procedures performed under general anesthesia or with a probe in the Eso.

Study limitations

In this study, the outer width of the Eso could not be measured. The measurements of the luminal width underestimates of the true caliber of the Eso. The wall thickness of the Eso is almost always <5 mm (6). Therefore, to avoid the possibility of esophageal injury, radiofrequency ablation was not performed within 5 mm of the esophageal lumen.

Because only two cine-fluoroscopic images were acquired during the procedure to minimize the number of images acquired, the measurements could not be made for each position of the Eso in real time. However, the position of the Eso was continually monitored during the procedure by fluoroscopy.

Clinical implications

Although atrioesophageal fistula formation is a rare complication of radiofrequency ablation of AF, it is associated with a high mortality rate (4). Various strategies may be utilized to avoid this complication, including the strategy used in the present study, which was to not deliver any radiofrequency energy at sites in contact with the Eso. Other strategies include markedly reducing the power and duration of radiofrequency energy applications or substituting cryoablation at sites that are in contact with the Eso. These strategies necessitate knowledge of the position of the Eso relative to the left atrium.

The present study demonstrates that esophageal mobility necessitates real-time imaging for an accurate awareness of the position of the Eso during AF ablation procedures. A computed tomography or magnetic resonance image performed several hours or days before an ablation procedure is unlikely to provide an accurate indication of the location of the Eso during the procedure, because of esophageal mobility that will almost certainly occur in the intervening period of time. This is likely to be the case even when digital fusion technology is used in the electrophysiology laboratory or when the procedures are performed under general anesthesia.

In most patients, barium paste coats the wall of the Eso, and residual barium often allows visualization of the Eso for 1 to 2 h after the initial barium swallow. Orally administered barium provides a simple, inexpensive, and safe way to accurately keep track of the Eso during an ablation procedure. However, to avoid the risk of aspiration, patients should receive little or no sedation before swallowing the barium.

References

- [1.](#) Gillinov AM , Pettersson G , Rice TW . Esophageal injury during radiofrequency ablation for atrial fibrillation . J Thorac Cardiovasc Surg . 2001;122:1239–1240 . [Full Text](#) | [Full-Text PDF \(52 KB\)](#) | [CrossRef](#)
- [2.](#) Mohr FW , Fabricius AM , Falk V , et al. Curative treatment of atrial fibrillation with intraoperative radiofrequency ablation (short-term and midterm results) . J Thorac Cardiovasc Surg . 2002;123:919–927 . [Abstract](#) | [Full Text](#) | [Full-Text PDF \(1114 KB\)](#) | [CrossRef](#)
- [3.](#) Sonmez B , Demirsoy E , Yagan N , et al. A fatal complication due to radiofrequency ablation for atrial fibrillation (atrio-esophageal fistula) . Ann Thorac Surg . 2003;76:281–283 . [MEDLINE](#) | [CrossRef](#)
- [4.](#) Pappone C , Oral H , Santinelli V , et al. Atrio-esophageal fistula as a complication of percutaneous transcatheter ablation of atrial fibrillation . Circulation . 2004;109:2724–2726 . [CrossRef](#)
- [5.](#) Scanavacca MI , D’Avila A , Parga J , Sosa E . Left atrial-esophageal fistula following radiofrequency catheter ablation of atrial fibrillation . J Cardiovasc Electrophysiol . 2004;15:960–962 . [MEDLINE](#)
- [6.](#) Lemola K , Sneider M , Desjardins B , et al. Computed tomographic analysis of the anatomy of the left atrium and the esophagus (implications for left atrial catheter ablation) . Circulation . 2004;110:3655–3660 . [CrossRef](#)
- [7.](#) Oral H , Chugh A , Lemola K , et al. Noninducibility of atrial fibrillation as an end point of left atrial circumferential ablation for paroxysmal atrial fibrillation (a randomized study) . Circulation . 2004;110:2797–2801 . [CrossRef](#)