1760_4-Stage_Vert_Card 10/9/08 2:34 PM Page 1

LUMBAR VERTEBRAE DEGENERATION

normal

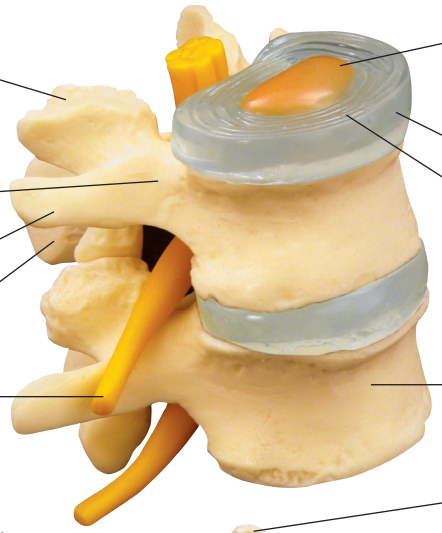

Superior articular process
Pedicle
Transverse process
Spinous process
Nerve
Nucleus pulposus
Nucleus pulposus with herniation
Intervertebral disc
Annulus fibrosus
Vertebral body

herniated disc

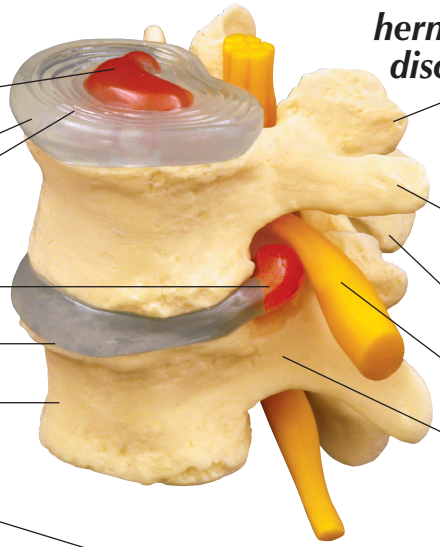

Herniated disc
Bulging disc
Superior articular process
Transverse process
Spinous process
Pinched nerve
Pedicle

bone/disc degeneration

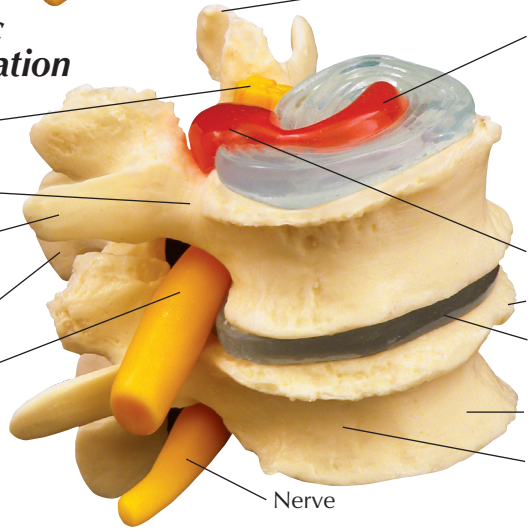

Spinal cord compression
Pedicle
Transverse process
Spinous process
Pinched nerve
Nerve
Superior articular process
Nucleus pulposus with herniation
Herniated disc
Bonespur
Disc compression
Vertebral body
Bone loss

advanced osteoporosis

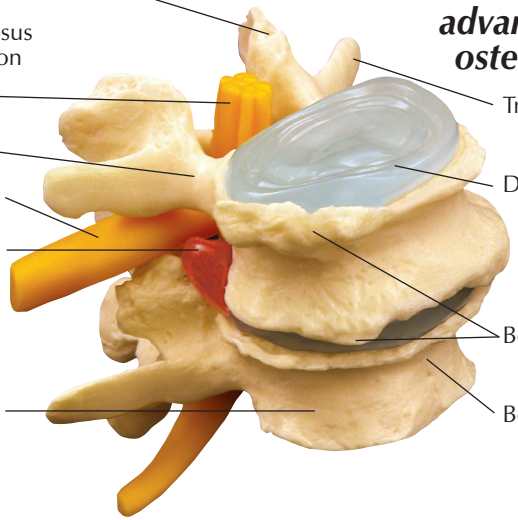

Spinal cord
Pedicle
Pinched nerve
Transverse process
Disc degeneration
Bonespur
Bone compression

GPI ©2004

www.gpianatomicals.com