

Transepithelial Iontophoresis Versus Standard Corneal Collagen Cross-linking: 1-Year Results of a Prospective Clinical Study

Paolo Vinciguerra, MD; Vito Romano, MD; Pietro Rosetta, MD; Emanuela F. Legrottaglie, MD; Raffaele Piscopo, MD; Claudia Fabiani, MD; Claudio Azzolini, MD; Riccardo Vinciguerra, MD

ABSTRACT

PURPOSE: To compare 1-year transepithelial corneal collagen cross-linking with iontophoresis (I-CXL) outcomes with standard CXL (S-CXL) epithelium-off for progressive keratoconus.

METHODS: Forty eyes of 40 patients with progressive keratoconus were included in this comparative, prospective clinical study. Corrected distance visual acuity (CDVA), spherical equivalent, cylinder refraction, corneal topography, Scheimpflug tomography, aberrometry, and endothelial cell count were assessed at baseline and at 1, 3, 6, and 12 months of follow-up.

RESULTS: Patients received either I-CXL (20 eyes) or S-CXL (20 eyes). Functional parameters (visual acuity and aberrometry) showed a significant improvement ($P < .05$) after 6 and 12 months of follow-up in both groups. In the I-CXL group, the CDVA showed a rapid recovery of vision after 3 months ($P = .01$) compared to baseline. Morphological parameters showed a significant reduction of maximum keratometry in the S-CXL group by -1.05 ± 1.51 diopters (D) after 12 months, whereas the I-CXL group curvature was stable (-0.31 ± 1.87 D). Minimum pachymetry values were stable even after 12 months of follow-up in the I-CXL group, whereas a significant corneal thinning 12 months following treatment was recorded in the S-CXL group ($P < .001$). None of the patients had continuous progression of keratoconus or had to repeat CXL procedures. Endothelial cell counts did not change significantly ($P > .05$).

CONCLUSIONS: The 1-year outcomes suggest that I-CXL might be comparable to S-CXL in stabilizing the progression of the degenerative ectatic disease. Additionally, quicker improvement of functional parameters was reported in the I-CXL group.

[*J Refract Surg.* 2016;32(10):672-678.]

Corneal collagen cross-linking (CXL) is currently the only treatment able to slow or halt the progression of ectatic disease.¹⁻⁴ Long-term follow-up studies on CXL refer to the standard technique (S-CXL), which entails epithelial debridement to allow riboflavin (hydrophilic) penetration in the corneal stroma; otherwise the corneal epithelium (lipophilic) reduces its permeability.⁵ Nevertheless, epithelial removal causes postoperative pain,⁶ delayed visual recovery,^{1,7,8} and increased risks of infection. Transepithelial cross-linking (TE-CXL) was introduced to avoid these threats. The original dextran-containing solutions have been reported to be ineffective for TE-CXL,⁹⁻¹¹ but other formulations of riboflavin (with chemical enhancers)¹² showed equivocal results in clinical studies.¹³⁻¹⁵ Conversely, preliminary results have shown that transepithelial cross-linking with iontophoresis (I-CXL) is able to increase the riboflavin concentration inside the stroma compared to other TE-CXL techniques together with histological changes.¹⁶⁻¹⁸ Pilot clinical findings using I-CXL with¹⁹ and without²⁰ epithelial removal have also reported encouraging results. In this study, we compared 1-year results of two groups of patients with keratoconus who

From Humanitas Clinical and Research Center, Milan, Italy (PV, PR, EFL, RP, CF); Humanitas University, Rozzano, Milan, Italy (PV); the Department of Corneal and External Eye Diseases, St. Paul's Eye Unit, Royal Liverpool University Hospital, Liverpool, United Kingdom (VR); and the Department of Surgical Sciences, Division of Ophthalmology, University of Insubria, Varese, Italy (CA, RV).

© 2016 Vinciguerra, Romano, Rosetta, et al.; licensee SLACK Incorporated. This is an Open Access article distributed under the terms of the Creative Commons Attribution 4.0 International (<https://creativecommons.org/licenses/by/4.0>). This license allows users to copy and distribute, to remix, transform, and build upon the article, for any purpose, even commercially, provided the author is attributed and is not represented as endorsing the use made of the work.

Submitted: March 6, 2016; Accepted: June 23, 2016

Dr. Paolo Vinciguerra is a consultant for Nidek and Oculus Optikgeräte, GmbH. The remaining authors have no financial or proprietary interest in the materials presented herein.

Drs. Riccardo Vinciguerra and Paolo Vinciguerra contributed equally to this work and should be considered as equal first authors.

Correspondence: Paolo Vinciguerra, MD, Istituto Clinico Humanitas, Via Manzoni 56, 20089 Rozzano, Milan, Italy. E-mail: paolo.vinciguerra@humanitas.it

doi:10.3928/1081597X-20160629-02

were treated with I-CXL and S-CXL (epithelium-off Dresden protocol).

PATIENTS AND METHODS

In this comparative, prospective, non-randomized, single-center interventional study, we included 40 eyes of 40 patients who underwent I-CXL or S-CXL at the Eye Center, Humanitas Clinical and Research Center (Rozzano, Milan, Italy). The inclusion criteria for the treatment of CXL were documentation of the progression of keratoconus and patients older than 9 years.⁷ Exclusion criteria were a history of herpetic keratitis, dry eye, severe corneal infection, concomitant ocular or systemic autoimmune disease, diagnosed pregnancy or breastfeeding, the presence of central or paracentral opacities, low compliance, and the use of rigid contact lenses for more than 4 weeks before the baseline evaluation.

The study received Institutional Review Board approval from the ethical committee of the Humanitas Clinical and Research Center and was conducted according to the tenets of the Declaration of Helsinki, as revised in 2000. All patients provided informed consent.

The following parameters were assessed in the preoperative and postoperative course (1, 3, 6, and 12 months): corrected distance visual acuity (CDVA), slit-lamp biomicroscopy, Goldmann tonometry, dilated funduscopy, corneal topography, and anterior corneal aberrometry for the evaluation of low and higher order aberrations (HOAs) (Costruzione Strumenti Oftalmici, Florence, Italy), optical tomography (Cirrus HD-OCT; Carl Zeiss Meditec, Dublin, CA), pachymetry with Pentacam (Oculus Optikgeräte, GmbH, Wetzlar, Germany), and endothelial biomicroscopy (Konan Specular Microscope; Konan Medical, Inc., Hyogo, Japan) before and 1 month after surgery.

The documentation of the progression and all preoperative and postoperative functional and morphological tests were performed in an identical manner to a previously published clinical study,²⁰ and postoperative complications were recorded.

The iontophoresis protocol entails the use of riboflavin solution specifically designed for the procedure, consisting of 0.1% riboflavin, no dextran or sodium chloride with the addition of two enhancers: ethylenediaminetetraacetic acid (EDTA) and trometamol (Ricola; Sooft, Montegiorgio, Italy). The corneal iontophoresis electrode was filled with approximately 0.5 mL of riboflavin solution from the open proximal side, until the electrode (stainless steel mesh) was covered. The device was then connected to a constant current generator (I-ON XL; Sooft) set at 1 mA (the total dose of 5 mA/5 minutes is monitored by

the generator). Subsequently, the cornea was irradiated at a working distance of 45 mm with an ultraviolet lamp of 10 mW (UV-X 2000; IROC Innocross AG, Zurich, Switzerland) for 9 minutes.²⁰ Conversely, the standard protocol, which we previously described in other publications,⁷ entails a 9-mm epithelial removal with an Amoils brush (Amoils Brush Epithelial Scrubber; Vision Technology Co., Seoul, Korea). A solution of riboflavin 0.1% and dextran 20% (Ricola; Sooft) was then instilled every minute for 30 minutes to fully irrigate the cornea. During irrigation, corneal thickness was tested using an ultrasound pachymeter (SP-2000; Tomey, Erlangen, Germany) to avoid exposing corneas to ultraviolet light when pachymetry was less than 400 μm . When required, a hypo-osmolar 0.1% riboflavin solution was instilled to promote corneal swelling. The last phase of the procedure includes ultraviolet-A irradiation, where a 7.5-mm diameter of the central cornea is treated with an irradiance of 3 mW/cm² (UV-X System; Peschke Meditrade GmbH, Huenenberg, Switzerland) for 30 minutes.

A soft therapeutic contact lens was applied in both groups, even if corneal epithelium was not removed in the I-CXL group, because the high intensity of ultraviolet light can damage the epithelium for the first days after the procedure. Postoperatively, an ophthalmic gel containing 0.15% sodium hyaluronate, 1% xanthan gum, and 0.3% netilmicin (Xanternet; SIFI SpA, Catania, Italy) was prescribed four times daily until no epithelium damage was seen (epithelial integrity was evaluated with fluorescein staining daily postoperatively) and, after removal of contact lens, dexamethasone 21-phosphate 0.15% drops (Etacortilen; Sifi, Lavinaio, Italy) were prescribed two times daily for 10 days and 0.15% sodium hyaluronate drops (BluYal; Sooft) were prescribed six times daily for 45 days. In addition, all patients received oral amino acid supplements (Aminoftal; Sooft) for 7 days.²¹

STATISTICAL ANALYSIS

Statistical analysis was performed using the SPSS statistical software (version 20.0; IBM Corp., Armonk, NY). Data are described as mean \pm standard deviation. The Shapiro–Wilks *W* test was performed to confirm the normality distribution of the data prior to analysis. The Student's *t* test for paired data was applied to assess the significance of differences between preoperative and postoperative data and an unpaired two-sided Student's *t* test was used to compare continuous variables. A linear regression analysis was performed for maximum keratometry (Kmax), CDVA, coma, and HOAs. A *P* value of less than .05 was considered significant in all cases.

TABLE 1
Comparison of S-CXL and I-CXL

Outcomes	Difference With Baseline at 12 Months		
	S-CXL	I-CXL	P
CDVA (logMAR)	-0.05 ± 0.11	-0.10 ± 0.10	.20
Sphere (D)	0.47 ± 1.15	0.90 ± 1.54	.30
Cylinder (D)	-0.43 ± 1.47	0.20 ± 1.39	.20
Kmax (D)	-1.05 ± 1.51	-0.31 ± 1.87	.008
SAI	-0.88 ± 1.50	-0.55 ± 1.52	.30
SI	-0.25 ± 1.48	1.06 ± 1.92	.50
ISV	-6.20 ± 11.28	0.60 ± 7.90	.04
IVA	-0.05 ± 0.19	-0.02 ± 0.12	.20
KI	-0.03 ± 0.04	0.08 ± 0.02	.0002
CKI	-0.02 ± 0.03	0.01 ± 0.02	.08
IHA	0.07 ± 28.4	-6.80 ± 16.98	.90
IHD	-0.01 ± 0.02	0.04 ± 0.14	.60
Rmin	0.21 ± 0.20	-0.06 ± 0.25	.0001
ThCT (μm)	-41.10 ± 35.30	1.00 ± 7.20	< .001
HOA	-0.03 ± 0.18	-0.33 ± 0.78	.01
Coma	-0.19 ± 0.31	-1.16 ± 1.64	.01
Ab sph	-0.02 ± 0.10	0.09 ± 0.56	< .001

S-CXL = standard corneal collagen cross-linking; I-CXL = transepithelial corneal collagen cross-linking with iontophoresis; CDVA = corrected distance visual acuity; sphere = spherical refraction; D = diopters; Kmax = maximum keratometry; SAI = surface asymmetry index; SI = symmetry index; ISV = index of surface variance; IVA = index of vertical asymmetry; KI = keratoconus index; CKI = central keratoconus index; IHA = index of height asymmetry; IHD = index of height decentration; Rmin = minimum radius of curvature; ThCT = minimum pachymetry; HOA = higher order aberrations; coma = comatic aberration; Ab sph = spherical aberration

RESULTS

Forty eyes of 40 patients were prospectively evaluated, 20 in each group (I-CXL and S-CXL). The mean age was 28.2 ± 8.5 years in the S-CXL group and 27.8 ± 6.4 years in the I-CXL group (the difference was not significant, $P = .86$). All patients had 1, 3, 6, and 12 months of follow-up, except in the I-CXL group where 1 patient was lost to follow-up at month 3 and 3 patients at month 12. Clinical features of the patients and their preoperative and follow-up data are listed in **Tables A-B** (available in the online version of the article), respectively.

Comparison at baseline demonstrated no significant difference in the biometric parameters, in particular the preoperative Kmax ($P = .10$), minimum pachymetry ($P = .67$), and progression rate (1.52 ± 0.70 D in the S-CXL group and 1.52 ± 0.20 D in the I-CXL group) ($P = .98$). **Table 1** shows the comparison between the groups.

FUNCTIONAL ANALYSIS

Visual Acuity. The statistical analysis showed a significant increase in CDVA compared to baseline in both

groups ($P < .05$). However, the I-CXL group already showed a significant increase in CDVA compared to baseline at the 3-month follow-up, whereas the S-CXL group improved significantly after 6 months. Linear regression analysis was significant in both groups, although it was stronger in the I-CXL group (I-CXL: $P = .0002$, $R = 0.98$; S-CXL: $P = .013$, $R = 0.6$), showing a quicker improvement in the I-CXL group compared to the S-CXL group (**Figure 1**).

Refractive Results. Spherical refraction showed a significant reduction ($P < .05$) at all postoperative follow-up times in the I-CXL group. Conversely, it was stable after S-CXL ($P > .05$). The results for cylinder variation after S-CXL presented a significant increase at months 1 and 3 compared to baseline, followed by a return to a nonsignificant improvement at the other follow-up times. Cylinder refraction also did not change significantly after I-CXL.

Aberrometric Results. Aberrometric results showed a significant worsening of HOAs, coma, and spherical aberration at month 1 ($P < .05$). Subsequently, coma and HOAs improved significantly, compared to baseline, after 6 and 12 months of follow-up in the I-CXL

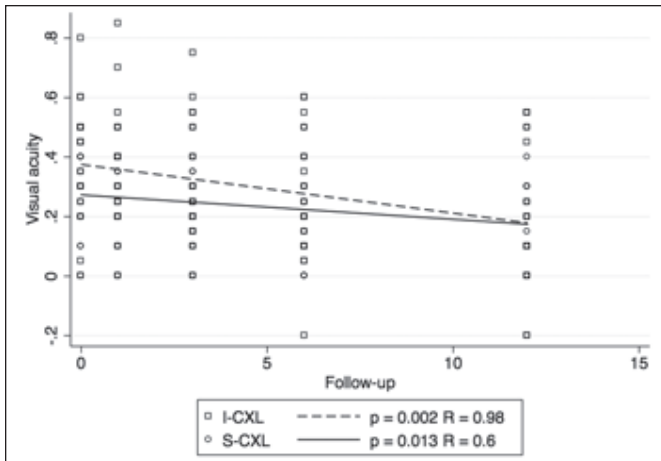


Figure 1. Linear regression analysis of corrected distance visual acuity expressed as logMAR (CDVA) in the corneal collagen cross-linking with iontophoresis (I-CXL) and standard CXL (S-CXL) groups.

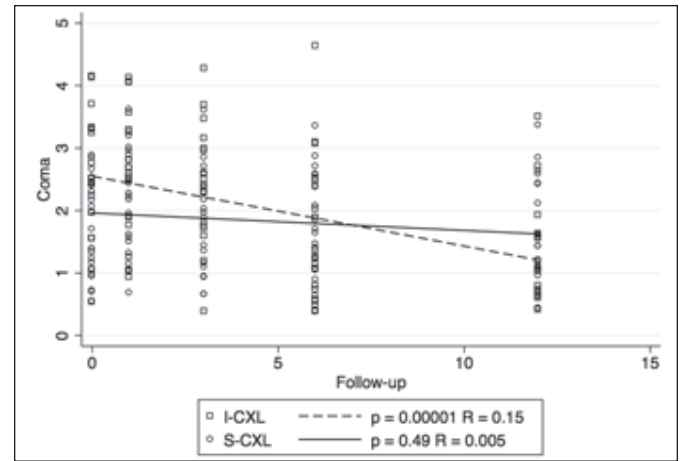


Figure 2. Linear regression analysis of comatic aberration in the corneal collagen cross-linking with iontophoresis (I-CXL) and standard CXL (S-CXL) groups.

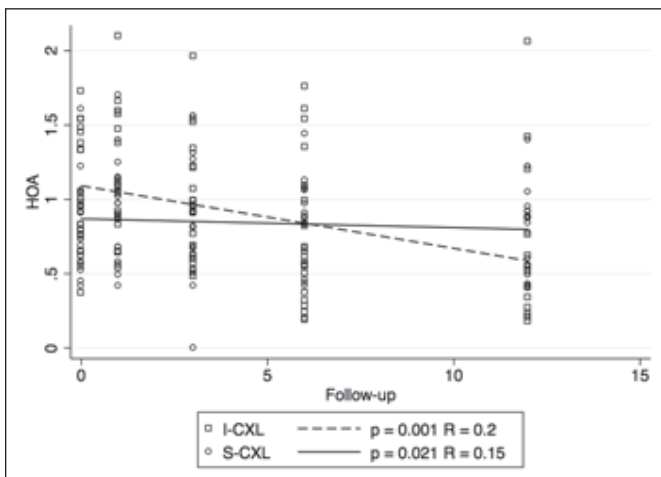


Figure 3. Linear regression analysis of higher order aberrations (HOAs) in the corneal collagen cross-linking with iontophoresis (I-CXL) and standard CXL (S-CXL) groups.

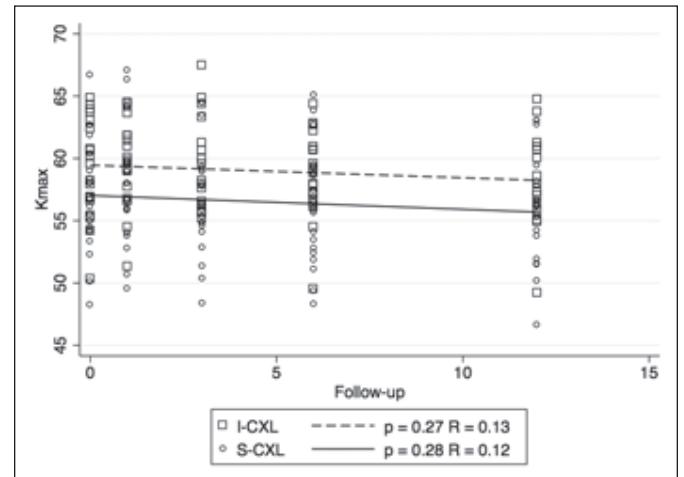


Figure 4. Linear regression analysis of maximum keratometry (Kmax) in the corneal collagen cross-linking with iontophoresis (I-CXL) and standard CXL (S-CXL) groups.

group, whereas the S-CXL group showed an improvement only in coma after 6 and 12 months. However, regression analysis of coma ($P = .0001$, $R = 0.15$) and HOAs ($P = .001$, $R = 0.20$) was significant in the I-CXL group (Figure 2) but not in the S-CXL group (coma: $P = .49$, $R = 0.005$; HOAs: $P = .021$, $R = 0.15$) (Figure 3).

Comparative analysis of the improvement induced by I-CXL compared to S-CXL regarding HOA and coma aberrations (Table 1) showed a significant difference between the groups: a reduction of $-1.16 \pm 1.64 \mu\text{m}$ for coma and $-0.33 \pm 0.78 \mu\text{m}$ for HOAs in the I-CXL group and $-0.19 \pm 0.31 \mu\text{m}$ for coma and $-0.03 \pm 0.18 \mu\text{m}$ for HOAs in the S-CXL group ($P = .01$).

STRUCTURAL ANALYSIS

Topographic Results. Topographic results for I-CXL and S-CXL are shown in Tables A-B. The morphologi-

cal indices indicate a stabilization of keratoconus in both groups. The analysis of the topographic results showed a significant worsening of numerous topographic indices and Kmax in either the S-CXL or I-CXL group at month 1. However, I-CXL did not cause a worsening of index of vertical asymmetry and index of height decentration, whereas S-CXL did. After this initial worsening, S-CXL induced a significant improvement of numerous topographic indices during the follow-up (Table B). In particular, Kmax was reduced significantly by $-1.05 \pm 1.51 \text{ D}$ after 12 months ($P < .01$). Conversely, I-CXL only showed a significant improvement of corneal symmetry index after 12 months of follow-up. The reduction of -0.31 ± 1.87 of Kmax did not reach statistical significance ($P = .20$). Comparative analysis showed a significant difference in the induced flattening between S-CXL and I-CXL ($P < .01$), with S-CXL performing better. However, linear regression

analysis was not significant in either group (I-CXL: $P = .27$, $R = 0.13$; S-CXL: $P = .28$, $R = 0.12$) (Figure 4).

Pachymetry Results. Pachymetry results for I-CXL and S-CXL are summarized in Tables A-B. The main result of this analysis is that there is a statistically significant thinning of the minimum corneal thickness in the S-CXL group ($P = .0001$), whereas this did not occur after I-CXL. Comparative analysis confirmed this result, showing an increase of minimum pachymetry of $1.0 \pm 7.2 \mu\text{m}$ after 12 months in the I-CXL group, whereas the S-CXL group showed a decrease of pachymetry of $-41.1 \pm 35.3 \mu\text{m}$ compared to baseline, even after 12 months of follow-up; this difference was statistically significant ($P < .001$).

As reported in a previous article,²⁰ no clear demarcation line was measurable with anterior segment optical coherence tomography, but an increase of anterior stroma reflectance was noted after I-CXL. After S-CXL, the demarcation line was clear and visible at the standard depth of an epithelium-off procedure.

All of the patients who underwent I-CXL revealed a punctate keratitis the first postoperative day. The contact lens was removed on the second day, except in 1 patient who showed a central erosion of the epithelium that healed in 2 days. Conversely, the contact lens in the S-CXL group was removed between 3 and 5 days postoperatively, when the cornea was reepithelialized.

None of the patients developed infection or haze, and no other complications occurred.

DISCUSSION

Due to the known limitations of CXL with epithelial removal, a CXL procedure that spares the epithelium while retaining maximal efficacy is highly desirable. To our knowledge, this is the first comparative prospective clinical study in which preoperative and postoperative refractive, topographic, tomographic, and aberrometric outcomes have been analyzed in eyes with progressive keratoconus treated with a commercial ocular iontophoresis device or standard Dresden protocol CXL.

In general, it is known that S-CXL with epithelial removal reduces or halts the progression of keratoconus, inducing significant improvements in morphological and functional parameters as shown in the S-CXL group and in previous reports,^{1,7} but the efficacy of I-CXL is unclear. Our results support the concept that I-CXL may be effective in halting the progression of keratoconus.

First, our study shows that I-CXL treatment stimulates a higher and quicker improvement of visual acuity compared to S-CXL. Given the stability induced by both protocols, this faster return to baseline CDVA is an important advantage of I-CXL.

Additionally, I-CXL promoted a greater reduction of HOAs and coma and it did not cause a decrease in minimum pachymetry. This last finding is relevant because it has been reported that a permanent stromal scar tends to develop in patients with thin corneas after S-CXL.^{2,7} No patients developed deep stromal opacities after I-CXL, even those who had a preoperative minimum corneal thickness less than $400 \mu\text{m}$. Moreover, minimum corneal thickness values were stable at up to 12 months of follow-up after I-CXL. There was a slight thinning of this value in the S-CXL group. Nevertheless, it is known that pachymetry values tend to increase after 12 to 24 months of follow-up with S-CXL.⁷

The I-CXL group showed a significant decrease in sphere values, whereas the S-CXL group was stable at 12 months of follow-up. Conversely, S-CXL induced a higher flattening effect together with a significant reduction of various topographic indexes. More long-term comparative studies will be needed to evaluate if the comparative outcomes of S-CXL and I-CXL will be different after 12 months of follow-up.

Anterior segment optical coherence tomography after I-CXL shows a completely different image compared to that after S-CXL. In S-CXL, an increase of reflectance with a white line (demarcation line) is normally visible.²² In I-CXL, it is possible to detect a similar increase of reflectance, but no white line is visible. This finding could be explained by either the different concentration gradient induced by I-CXL or a reduced CXL effect.

These results highlight the clinical efficacy of I-CXL to overcome the problems of TE-CXL: the penetration of riboflavin through the epithelium. It is known that the corneal epithelium and Bowman's layer mostly absorb ultraviolet-B light (up to 300 nm) but they allow penetration of ultraviolet-A light.²³ Bottós et al. showed that the reduced effect of TE-CXL compared to S-CXL is principally due to the limited penetration of riboflavin through the epithelium, and confirmed that it is not a barrier to ultraviolet-A transmittance.²⁴

However, it is known from preclinical reports that the biomechanical effect, riboflavin penetration, and distribution of I-CXL are higher than in TE-CXL but lower when compared to S-CXL.^{17,18,25} This comparative clinical study will continue the follow-up of the patients to determine whether this stiffening effect, even if reduced, will be enough to halt the ectatic disease in the long term.

As previously reported,²⁰ our findings are in partial agreement with the 1-year follow-up report by Bikbova and Bikbov²⁶ of 9 patients treated with I-CXL. Their results showed that I-CXL is able to halt the progression of keratoconus, but they did not report any significant

change in functional parameters, only a significant decrease in corneal thickness after 6 months of follow-up. We previously described the differences between the two studies and the limitations of the considered report.²⁰

Our findings are in agreement with a preliminary, unpublished, 6-month follow-up report of a randomized, controlled, prospective comparative clinical study of I-CXL versus S-CXL that showed comparable results of the two protocols.²⁷ However, in this study, the I-CXL procedure was modified using a Biopore membrane to remove the mucin layer.

The principal limits of our study are the relatively small number of patients and the 1-year follow-up, which might be not sufficient to judge the safety and efficacy of this transepithelial approach. The energy dose used may be a further limitation. The total energy dose of 5.4 J/cm² was applied to be comparable to all other historical published S-CXL^{1,2} and TE-CXL²⁸ studies that chose this dose. However, Zhang et al. showed that the epithelial cells are not enriched with riboflavin.²⁸ For that reason, only part of the ultraviolet light should be absorbed by the epithelium, approximately 15% to 20%.²⁹ Therefore, it could be advisable to increase the energy dose in I-CXL by 20% to 6.5 J/cm².

This comparative prospective clinical study demonstrated that I-CXL has the potential to become a valid alternative to halt the progression of keratoconus while reducing patients' postoperative pain, risk of infection, and treatment time.

AUTHOR CONTRIBUTIONS

Study concept and design (PV, RV); data collection (PR, EFL, RP, CF, RV); analysis and interpretation of data (PV, VR, CA, RV); writing the manuscript (VR, RV); critical revision of the manuscript (PV, PR, EFL, RP, CF, CA, RV); statistical expertise (VR); administrative, technical, or material support (PV); supervision (PV)

REFERENCES

- Vinciguerra P, Albè E, Trazza S, et al. Refractive, topographic, tomographic, and aberrometric analysis of keratoconic eyes undergoing corneal cross-linking. *Ophthalmology*. 2009;116:369-378.
- Raiskup-Wolf F, Hoyer A, Spoerl E, Pillunat LE. Collagen cross-linking with riboflavin and ultraviolet-A light in keratoconus: long-term results. *J Cataract Refract Surg*. 2008;34:796-801.
- Wollensak G, Spoerl E, Seiler T. Riboflavin/ultraviolet-a-induced collagen crosslinking for the treatment of keratoconus. *Am J Ophthalmol*. 2003;135:620-627.
- Caporossi A, Mazzotta C, Baiocchi S, Caporossi T. Long-term results of riboflavin ultraviolet a corneal collagen cross-linking for keratoconus in Italy: the Siena Eye Cross Study. *Am J Ophthalmol*. 2010;149:585-593.
- Huang AJ, Tseng SC, Kenyon KR. Paracellular permeability of corneal and conjunctival epithelia. *Invest Ophthalmol Vis Sci*. 1989;30:684-689.
- Ghanem VC, Ghanem RC, de Oliveira R. Postoperative pain after corneal collagen cross-linking. *Cornea*. 2013;32:20-24.
- Vinciguerra R, Romano MR, Camesasca FI, et al. Corneal cross-linking as a treatment for keratoconus: four-year morphologic and clinical outcomes with respect to patient age. *Ophthalmology*. 2013;120:908-916.
- Dhawan S, Rao K, Natrajan S. Complications of corneal collagen cross-linking. *J Ophthalmol*. 2011;2011:869015.
- Caporossi A, Mazzotta C, Paradiso AL, et al. Transepithelial corneal collagen crosslinking for progressive keratoconus: 24-month clinical results. *J Cataract Refract Surg*. 2013;39:1157-1163.
- Leccisotti A, Islam T. Transepithelial corneal collagen cross-linking in keratoconus. *J Refract Surg*. 2010;26:942-948.
- Soeters N, Wisse RP, Godefrooij DA, Imhof SM, Tahzib NG. Transepithelial versus epithelium-off corneal cross-linking for the treatment of progressive keratoconus: a randomized controlled trial. *Am J Ophthalmol*. 2015;159:821-828.
- Gore DM, O'Brart D, French P, Dunsby C, Allan BD. Transepithelial riboflavin absorption in an ex vivo rabbit corneal model. *Invest Ophthalmol Vis Sci*. 2015;56:5006-5011.
- Filippello M, Stagni E, O'Brart D. Transepithelial corneal collagen crosslinking: bilateral study. *J Cataract Refract Surg*. 2012;38:283-291. Erratum in: *J Cataract Refract Surg*. 2012;38:1515.
- Magli A, Forte R, Tortori A, Capasso L, Marsico G, Piozzi E. Epithelium-off corneal collagen cross-linking versus transepithelial cross-linking for pediatric keratoconus. *Cornea*. 2013;32:597-601.
- Rossi S, Orrico A, Santamaria C, et al. Standard versus transepithelial collagen cross-linking in keratoconus patients suitable for standard collagen cross-linking. *Clin Ophthalmol*. 2015;9:503-509.
- Mastropasqua L, Lanzini M, Curcio C, et al. Structural modifications and tissue response after standard epi-off and iontophoretic corneal crosslinking with different irradiation procedures. *Invest Ophthalmol Vis Sci*. 2014;55:2526-2533.
- Mastropasqua L, Nubile M, Calienno R, et al. Corneal cross-linking: intrastromal riboflavin concentration in iontophoresis-assisted imbibition versus traditional and transepithelial techniques. *Am J Ophthalmol*. 2014;157:623-630.
- Cassagne M, Laurent C, Rodrigues M, et al. Iontophoresis trans-corneal delivery technique for transepithelial corneal collagen crosslinking with riboflavin in a rabbit model. *Invest Ophthalmol Vis Sci*. 2016;57:594-603.
- Vinciguerra P, Romano V, Rosetta P, et al. Iontophoresis-assisted corneal collagen cross-linking with epithelial debridement: preliminary results. *BioMed Res Int*. 2016;2016:3720517.
- Vinciguerra P, Randleman JB, Romano V, et al. Transepithelial iontophoresis corneal collagen cross-linking for progressive keratoconus: initial clinical outcomes. *J Refract Surg*. 2014;30:746-753.
- Torres Munoz I, Grizzi F, Russo C, Camesasca FI, Dioguardi N, Vinciguerra P. The role of amino acids in corneal stromal healing: a method for evaluating cellular density and extracellular matrix distribution. *J Refract Surg*. 2003;19(2 suppl):S227-S230.
- Doors M, Tahzib NG, Eggink FA, et al. Use of anterior segment optical coherence tomography to study corneal changes after collagen cross-linking. *Am J Ophthalmol*. 2009;148:844-851.
- Kolozsvári L, Nográdi A, Hopp B, Bor Z. UV absorbance of the human cornea in the 240- to 400-nm range. *Invest Ophthalmol Vis Sci*. 2002;43:2165-2168.

24. Bottós KM, Schor P, Dreyfuss JL, Nader HB, Chamon W. Effect of corneal epithelium on ultraviolet-A and riboflavin absorption. *Arq Bras Ophthalmol.* 2011;74:348-351.
25. Vinciguerra P, Mencucci R, Romano V, et al. Imaging mass spectrometry by matrix-assisted laser desorption/ionization and stress-strain measurements in iontophoresis transepithelial corneal collagen cross-linking. *Biomed Res Int.* 2014;2014:404587.
26. Bikbova G, Bikbov M. Transepithelial corneal collagen cross-linking by iontophoresis of riboflavin. *Acta Ophthalmol.* 2014;92:e30-e34.
27. Lombardo G, Rosati M, Schiano-Lamoriello D, Lombardo M. A randomized, controlled trial of transepithelial corneal cross-linking using iontophoresis in progressive keratoconus: technique and six months results. *Invest Ophthalm Vis Sci.* 2016;56:ARVO E-Abstract 2892.
28. Zhang Y, Sukthankar P, Tomich JM, Conrad GW. Effect of the synthetic NC-1059 peptide on diffusion of riboflavin across an intact corneal epithelium. *Invest Ophthalmol Vis Sci.* 2012;53:2620-2629.
29. Spoerl E. Corneal collagen cross-linking epithelium-on versus epithelium-off treatments. In: Hafezi F, Randleman JB, eds. *Corneal Collagen Cross-Linking.* Thorofare, NJ: SLACK Incorporated; 2013:139-142.

TABLE A
Transepithelial Corneal Collagen Cross-linking With Iontophoresis Data

Outcomes	Baseline	1 Month	P	3 Months	P	6 Months	P	12 Months	P
CDVA (logMAR)	0.25 ± 0.15	0.25 ± 0.22	.13	0.20 ± 0.18	.01	0.12 ± 0.13	.0004	0.12 ± 0.15	.0003
Sphere (D)	-2.03 ± 2.89	-1.42 ± 2.42	.06	-1.31 ± 2.72	.003	-1.13 ± 3.06	.001	-1.14 ± 2.72	.02
Cylinder (D)	-3.16 ± 1.31	-3.18 ± 1.21	.86	-3.28 ± 1.31	.55	-3.40 ± 1.44	.27	-3.03 ± 1.47	.56
Kmax (D)	59.07 ± 3.90	59.63 ± 3.44	.05	59.45 ± 3.71	.96	58.69 ± 3.45	.35	58.22 ± 3.90	.44
SAI	7.79 ± 3.86	8.27 ± 3.82	.01	7.65 ± 3.76	.70	7.51 ± 3.81	.55	6.65 ± 3.55	.15
SI	8.98 ± 5.06	9.53 ± 5.21	.07	9.62 ± 4.96	.18	9.82 ± 5.23	.08	8.97 ± 4.64	.04
ECD (µm)	2,446 ± 209.7	2,508 ± 226.12	.40	-	-	-	-	-	-
ISV	106.68 ± 31.51	109.2 ± 31.34	.0013	105.68 ± 32.52	.50	107.72 ± 33.35	.69	97.56 ± 29.01	.77
IVA	1.20 ± 0.44	1.19 ± 0.43	.20	1.16 ± 0.45	.78	1.19 ± 0.46	.73	1.04 ± 0.38	.47
KI	1.29 ± 0.11	8.03 ± 30.12	.30	1.28 ± 0.10	.77	1.30 ± 0.12	.34	1.26 ± 0.10	.24
CKI	1.06 ± 0.04	1.08 ± 0.03	.0025	1.07 ± 0.03	.02	1.07 ± 0.03	.04	1.07 ± 0.03	.05
IHA	31.65 ± 22.55	30.51 ± 26.49	.88	28.64 ± 24.04	.76	26.93 ± 18.79	.57	20.35 ± 14.39	.14
IHD	0.11 ± 0.04	0.11 ± 0.04	.40	0.13 ± 0.11	.37	0.11 ± 0.04	.54	0.13 ± 0.15	.30
Rmin	5.88 ± 0.49	5.81 ± 0.45	.15	5.84 ± 0.48	.22	5.93 ± 0.54	.61	5.91 ± 0.46	.34
ThCT (µm)	434.31 ± 37.84	436.1 ± 38.37	.60	440.73 ± 38.59	.44	444.1 ± 37.23	.30	443.1 ± 36.37	.67
HOA	1.04 ± 0.39	1.12 ± 0.43	.01	0.99 ± 0.42	.45	0.74 ± 0.50	.007	0.62 ± 0.53	.0026
Coma	2.40 ± 1.03	2.56 ± 0.96	.0006	2.42 ± 0.96	.59	1.65 ± 1.14	.006	1.27 ± 0.86	.003
Ab sph	0.14 ± 0.44	0.386 ± 0.49	.03	0.13 ± 0.76	.48	0.29 ± 0.39	.12	0.26 ± 0.42	.77

CDVA = corrected distance visual acuity; sphere= spherical refraction; D = diopters; Kmax = maximum keratometry; SAI = surface asymmetry index; SI = symmetry index; ECD = endothelial cell density; ISV = index of surface variance; IVA = index of vertical asymmetry; KI = keratoconus index; CKI = central keratoconus index; IHA = index of height asymmetry; IHD = index of height decentration; Rmin = minimum radius of curvature; ThCT = minimum pachymetry; HOA = higher order aberrations; coma = comatic aberration; Ab sph = spherical aberration
 Bold values indicate statistical significance.

TABLE B
Standard Corneal Collagen Cross-linking Data

Outcomes	Baseline	1 Month	P	3 Months	P	6 Months	P	12 Months	P
CDVA (logMAR)	0.16 ± 0.08	0.15 ± 0.08	.70	0.12 ± 0.08	.10	0.10 ± 0.08	.04	0.10 ± 0.08	.03
Sphere (D)	-0.85 ± 2.16	-0.97 ± 2.23	.60	-0.55 ± 2.14	.10	-0.36 ± 2.26	.10	-0.37 ± 2.07	.08
Cylinder (D)	-2.52 ± 1.65	-3.21 ± 1.75	.01	-3.28 ± 1.57	.01	-3.03 ± 1.25	.10	-2.96 ± 1.21	.20
Kmax (D)	56.87 ± 4.52	57.36 ± 4.63	.30	56.5 ± 4.35	.40	56.11 ± 4.61	.05	55.82 ± 4.29	.005
SAI	6.03 ± 3.29	6.95 ± 3.36	.0007	6.31 ± 3.05	.20	9.57 ± 19.29	.30	5.15 ± 3.00	.01
SI	7.29 ± 3.83	7.96 ± 3.84	.02	7.56 ± 3.68	.20	7.21 ± 4.05	.70	7.04 ± 3.85	.40
ECD (µm)	2,526 ± 385.5	2,200 ± 122.7	.40	-	-	-	-	-	-
ISV	79.65 ± 29.39	91.6 ± 27.3	.001	83.9 ± 29.3	.10	76.95 ± 31.22	.20	73.45 ± 28.52	.02
IVA	0.92 ± 0.44	1.08 ± 0.37	.003	1.00 ± 0.39	.60	0.91 ± 0.44	.90	0.86 ± 0.40	.20
KI	1.21 ± 0.09	1.24 ± 0.10	.07	1.21 ± 0.09	.50	1.19 ± 0.11	.04	1.18 ± 0.10	.001
CKI	1.08 ± 0.03	1.05 ± 0.05	.001	1.05 ± 0.06	.10	1.02 ± 0.04	.004	1.01 ± 0.05	.006
IHA	20.88 ± 19.43	26.58 ± 23.32	.30	19.37 ± 15.27	.60	19.32 ± 14.94	.60	20.95 ± 22.20	.90
IHD	0.08 ± 0.04	0.09 ± 0.04	.02	0.13 ± 0.23	.30	0.07 ± 0.04	.10	0.07 ± 0.04	.01
Rmin	6.31 ± 0.58	6.20 ± 0.57	.01	6.35 ± 0.60	.30	6.49 ± 0.64	.0008	6.53 ± 0.62	.0001
ThCT (µm)	472.65 ± 32.86	437.3 ± 36.99	.0001	425.95 ± 35.64	.0001	429.3 ± 42.08	.0001	431.5 ± 49.9	.0001
HOA	0.83 ± 0.28	0.93 ± 0.31	.01	0.81 ± 0.34	.70	0.83 ± 0.25	.90	0.80 ± 0.26	.40
Coma	1.84 ± 0.82	2.09 ± 0.83	.002	1.87 ± 0.81	.60	1.71 ± 0.83	.02	1.65 ± 0.83	.01
Ab sph	0.003 ± 0.33	0.087 ± 0.37	.01	0.02 ± 0.34	.30	0.008 ± 0.34	.80	0.26 ± 0.42	.20

CDVA = corrected distance visual acuity; sphere= spherical refraction; D = diopters; Kmax = maximum keratometry; SAI = surface asymmetry index; SI = symmetry index; ECD = endothelial cell density; ISV = index of surface variance; IVA = index of vertical asymmetry; KI = keratoconus index; CKI = central keratoconus index; IHA = index of height asymmetry; IHD = index of height decentration; Rmin = minimum radius of curvature; ThCT = minimum pachymetry; HOA = higher order aberrations; coma = comatic aberration; Ab sph = spherical aberration
 Bold values indicate statistical significance.