

## Retinal Atrophy in Albino Rats Associated with *Pituranthos triradiatus* (Umbelliferae)-Induced Photosensitization

A. Nyska, Y. R. Bar Ishak, D. Ashkenazy, J. Friedman, Y. Kashman and J. Lelyveld

*Vet Pathol* 1984 21: 551

DOI: 10.1177/030098588402100524

The online version of this article can be found at:

<http://vet.sagepub.com/content/21/5/551>

---

Published by:



<http://www.sagepublications.com>

On behalf of:

[American College of Veterinary Pathologists](#), [European College of Veterinary Pathologists](#), & [the Japanese College of Veterinary Pathologists](#).

**Additional services and information for *Veterinary Pathology Online* can be found at:**

**Email Alerts:** <http://vet.sagepub.com/cgi/alerts>

**Subscriptions:** <http://vet.sagepub.com/subscriptions>

**Reprints:** <http://www.sagepub.com/journalsReprints.nav>

**Permissions:** <http://www.sagepub.com/journalsPermissions.nav>

>> [Version of Record](#) - Sep 1, 1984

[What is This?](#)

## Retinal Atrophy in Albino Rats Associated with *Pituranthos triradiatus* (Umbelliferae)-Induced Photosensitization

A. NYSKA, Y. R. BAR ISHAK, D. ASHKENAZY, J. FRIEDMAN, Y. KASHMAN, and J. LELYVELD

*Pituranthos triradiatus* is a common perennial in the Negev desert and although its dense tufts are green all the year, it only occasionally is grazed by goats or gazelles (D. Ashkenazy, personal communication). Five furocoumarins were detected in the shoots of this plant.<sup>1</sup> Some furocoumarins present in different members of the Umbelliferae are known to induce photosensitization in various animals (ducks, sheep, geese). These are manifested by lesions in the skin and globes.<sup>2,4,6</sup> Since there is no information on the photosensitizing effect of furocoumarins on the eyes of albino rats, we studied the effects of *Pituranthos triradiatus* on albino rats, with particular emphasis on histology of the globes.

Two groups (ten each) of female albino rats (Sabra, Tel Aviv, 210-230 g/rat), received 1 g/day of dried, ground shoots of *Pituranthos triradiatus* for ten days. The plant material was mixed with 3 g bread, 4 g whole raw egg and 0.50 g of soya oil. After the rats had consumed this mixture, Labena (Assia-Maabarot, Israel) rat food and tap water were supplied *ad libitum*. The first group was exposed to direct sunlight for eight hours daily during the experimental period, whereas the second group was kept in the shade. A third group used as a control (ten rats) was fed no *Pituranthos triradiatus* and exposed to sunlight for the same period. All groups were maintained for an additional ten days under the same illumination, but fed commercial rat food. The rats were then killed and their globes were fixed in Davidson's fluid and examined histologically. Five  $\mu\text{m}$  sections were cut and stained with hematoxylin and eosin (HE) and periodic acid-Schiff.

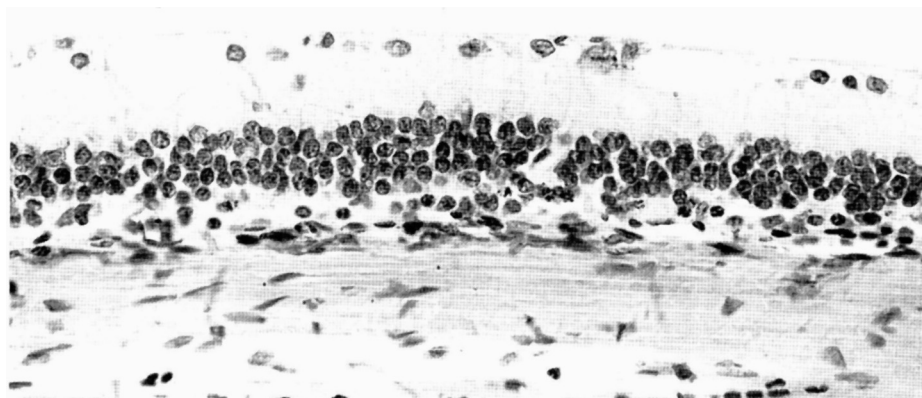
Gross and microscopic changes were seen only in rats which were fed the plant and exposed to sunlight. Externally, the dorsal aspect of the paw skin, the tip of the tail and periorbital skin were erythematous. In addition, from day four of feeding, erythematous areas on the ears became progressively ulcerated, encrusted, fibrotic, and deformed.

All ten rats of the first group had histological lesions of the same severity which were exactly reproduced in a similar later experiment. The lesions were confined to the retina and were located at the posterior pole. They consisted of areas of atrophy of the external retinal layers (fig. 1). In these areas the retinal pigmented epithelium and the layer of rods and cones was absent. The choriocapillaris also was missing. The outer nuclear layer was reduced to a single layer of degenerating cells with pyknotic nuclei or had disappeared completely. There was no outer plexiform layer and focally, the inner and outer nuclear layers were fused.

Towards the periphery of the retina, flattened retinal pigmented epithelial cells, the rods and cones, and outer plexiform layer appeared and gradually acquired normal width. Vacuolization in the inner nuclear, outer plexiform, and ganglion cell layers was seen in the areas of the retina surrounding the focus of photodynamic retinopathy.

The characteristic lesion was loss of the external retinal layers at the posterior pole. It is likely that more light reached the affected area. This emphasizes the importance of sunlight in the induction of these lesions.

The vacuolization observed in the inner retinal layers seems to be secondary to the main lesion in the external retinal



**Fig. 1:** Albino rat fed *Pituranthos triradiatus* and exposed to sunlight. Posterior pole of retina near optic disc. No pigment epithelium and photoreceptors. Few remaining pyknotic cells of external nuclear layer fused to inner nuclear layer. Occasional cystic cavities in ganglion cell layer. HE.

layers. It is difficult to determine whether this degenerating lesion starts at the retinal pigmented epithelial cells and later causes destruction of the rods and cones and outer nuclear layer, or whether it involves the retinal pigmented epithelium and the external retinal layers at the same time. Perhaps the photodynamic agent in the *Pituranthos triradiatus* reaches, via the choriocapillaris, all the external retinal layers and is activated and thus turned into a destructive substance for the retinal cells under the effect of sunlight. It is difficult to explain the fact that no such degenerating lesions could be seen in the inner retinal layers which get their nutrition through the retinal vessels.

We assume that the retinal pigmented epithelium and the external retinal layers have a particular sensitivity. There was no periodic collection of specimens during the duration of exposure. The histological changes observed at the periphery of the lesion may represent the changes obtained with a reduced amount of *Pituranthos triradiatus* ingestion, or a reflection of the amount of exposure to light. In another experiment with *Pituranthos triradiatus*, conducted under the same conditions in guinea pigs, ducks, albino mice, and albino and pigmented rabbits, only the ducks manifested ocular changes. In those animals, there was atrophy of the sphincter pupillary muscle associated with ectropium uvea. Similar lesions were found in ducklings after ingestion of *Ammi majus* followed by exposure to sunlight.<sup>4</sup>

The retina of albino rats must have a special sensitivity.

We found no mention of such a sensitivity in the literature. This retinal atrophy is similar to atrophy of the retina observed in rats,<sup>3</sup> and mice<sup>5</sup> exposed to light conditions considered normal in man. However, in those experimental studies, the retinal atrophy was obtained without the presence of photodynamic agents and under long periods of light exposure.

#### References

- 1 ASHKENAZY, D.; FRIEDMAN, J.; KASHMAN, Y.: The furocoumarin composition of *Pituranthos triradiatus*. *Planta Med* 47:218-220, 1983
- 2 BAR ISHAK, Y.R.; BEEMER, A.M.; EGYED, M.N.; SHLOSBERG, A.; EILAT, A.: Histology of the iris of geese and ducks photosensitized by ingestion of *Ammi majus* seeds. *Acta Ophthalmol* 53:585-590, 1975
- 3 BELHORN, R.W.: Lighting in the animal environment. *Lab Anim Sci* 30:440-448, 1980
- 4 EGYED, M.N.; SHLOSBERG, A.; EILAT, A.; MALKISON, M.: Acute and chronic manifestations of *Ammi majus* induced photosensitization in ducks. *Vet Rec* 977:198-199, 1975
- 5 GREENMAN, D.L.; BRYANT, P.; KODELL, R.L.; SHELDON, W.: Influence of cage shelf level on retinal atrophy in mice. *Lab Anim Sci* 32:353-356, 1982
- 6 WITZEL, D.A.; DOLLATRITTE, J.W.; JONES, L.P.: Photosensitization in sheep fed *Ammi majus* (Bishop's weed) seed. *Am J Vet Res* 39:319-320, 1978