



## Peroxisome biogenesis disorders in the Zellweger spectrum: An overview of current diagnosis, clinical manifestations, and treatment guidelines



Nancy E. Braverman<sup>a</sup>, Gerald V. Raymond<sup>b</sup>, William B. Rizzo<sup>c</sup>, Ann B. Moser<sup>d</sup>, Mark E. Wilkinson<sup>e</sup>, Edwin M. Stone<sup>e</sup>, Steven J. Steinberg<sup>f</sup>, Michael F. Wangler<sup>g</sup>, Eric T. Rush<sup>h</sup>, Joseph G. Hacia<sup>i</sup>, Mousumi Bose<sup>j,\*</sup>

<sup>a</sup> McGill University Health Centre, 1001 Décarie Blvd Block E, EM02230, Montreal, QC H4A3J1, Canada

<sup>b</sup> Department of Neurology, University of Minnesota, 516 Delaware Street SE, Minneapolis, MN 55455, USA

<sup>c</sup> Department of Pediatrics, University of Nebraska Medical Center, 985456 Nebraska Medical Center – MMI 3062, Omaha, NE 68198-5456, USA

<sup>d</sup> Hugo W. Moser Research Institute at Kennedy Krieger, 707 N. Broadway, Baltimore, MD 21205, USA

<sup>e</sup> Carver College of Medicine, Department of Ophthalmology and Visual Sciences, University of Iowa, Stephen A. Wynn Institute for Vision Research, 200 Hawkins Drive, Iowa City, IA 52242, USA

<sup>f</sup> Institute of Genetic Medicine and Department of Neurology, Johns Hopkins University School of Medicine, CMSC1004B, 600 N Wolfe Street, Baltimore, MD 21287, USA

<sup>g</sup> Department of Molecular and Human Genetics, Baylor College of Medicine, Duncan Neurological Research Institute, DNRI-1050, Houston, TX 77030, USA

<sup>h</sup> Munroe-Meyer Institute for Genetics and Rehabilitation, University of Nebraska Medical Center, 985440 Nebraska Medical Center, Omaha, NE 68198, USA

<sup>i</sup> Department of Biochemistry and Molecular Biology, University of Southern California, 1975 Zonal Ave, Los Angeles, CA 90033, USA

<sup>j</sup> Global Foundation for Peroxisomal Disorders, 5147 S. Harvard Avenue, Suite 181, Tulsa, OK 74135, USA

### ARTICLE INFO

#### Article history:

Received 31 October 2015

Received in revised form 21 December 2015

Accepted 21 December 2015

Available online 23 December 2015

#### Keywords:

Peroxisome biogenesis disorders

Zellweger spectrum disorder

Treatment guidelines

PEX genes

Very long-chain fatty acids

Sensorineural hearing loss

Retinal dystrophy

### ABSTRACT

Peroxisome biogenesis disorders in the Zellweger spectrum (PBD-ZSD) are a heterogeneous group of genetic disorders caused by mutations in *PEX* genes responsible for normal peroxisome assembly and functions. As a result of impaired peroxisomal activities, individuals with PBD-ZSD can manifest a complex spectrum of clinical phenotypes that typically result in shortened life spans. The extreme variability in disease manifestation ranging from onset of profound neurologic symptoms in newborns to progressive degenerative disease in adults presents practical challenges in disease diagnosis and medical management. Recent advances in biochemical methods for newborn screening and genetic testing have provided unprecedented opportunities for identifying patients at the earliest possible time and defining the molecular bases for their diseases. Here, we provide an overview of current clinical approaches for the diagnosis of PBD-ZSD and provide broad guidelines for the treatment of disease in its wide variety of forms. Although we anticipate future progress in the development of more effective targeted interventions, the current guidelines are meant to provide a starting point for the management of these complex conditions in the context of personalized health care.

© 2015 Elsevier Inc. All rights reserved.

### Contents

1. Definition, nomenclature, and epidemiology . . . . .	314
2. Laboratory diagnostic criteria . . . . .	315
2.1. Traditional biochemical testing . . . . .	315
2.2. Genetic diagnostic testing . . . . .	315
2.3. Newborn screening . . . . .	315
2.4. Prenatal diagnosis of PBD-ZSD . . . . .	316

**Abbreviations:** AAV, adeno-associated virus; AED, anti-epileptic drug(s); DHA, docosahexaenoic acid; DHCA, dihydroxycholestanic acid; ERG, electroretinogram; G-tube, gastrostomy tube; IRD, infantile Refsum disease; LC-MS/MS, liquid chromatography/tandem mass spectrometry; NALD, neonatal adrenoleukodystrophy; OCT, optical coherence tomography; PBD, peroxisome biogenesis disorder; PBD-ZSD, peroxisome biogenesis disorder-Zellweger spectrum disorder; THCA, trihydroxycholestanic acid; VLCFA, very long chain fatty acid(s); X-ALD, X-linked adrenoleukodystrophy; ZS, Zellweger syndrome.

\* Corresponding author.

**E-mail addresses:** [nancy.braverman@mcgill.ca](mailto:nancy.braverman@mcgill.ca) (N.E. Braverman), [gvrayment@umn.edu](mailto:gvrayment@umn.edu) (G.V. Raymond), [wrizzo@umnc.edu](mailto:wrizzo@umnc.edu) (W.B. Rizzo), [mosera@kennedykrieger.org](mailto:mosera@kennedykrieger.org) (A.B. Moser), [mark-wilkinson@uiowa.edu](mailto:mark-wilkinson@uiowa.edu) (M.E. Wilkinson), [edwin-stone@uiowa.edu](mailto:edwin-stone@uiowa.edu) (E.M. Stone), [ssteinb8@jhmi.edu](mailto:ssteinb8@jhmi.edu) (S.J. Steinberg), [michael.wangler@bcm.edu](mailto:michael.wangler@bcm.edu) (M.F. Wangler), [erush@umnc.edu](mailto:erush@umnc.edu) (E.T. Rush), [hacia@usc.edu](mailto:hacia@usc.edu) (J.G. Hacia), [mousumi@thefpd.org](mailto:mousumi@thefpd.org) (M. Bose).

3.	Management and treatment guidelines . . . . .	316
3.1.	Clinical evaluations following initial diagnosis . . . . .	316
3.2.	Feeding and nutrition . . . . .	317
3.3.	Liver . . . . .	318
3.4.	Hearing . . . . .	318
3.5.	Vision . . . . .	318
3.6.	Neurological function . . . . .	318
3.7.	Bone . . . . .	318
3.8.	Teeth . . . . .	318
3.9.	Adrenal insufficiency . . . . .	318
3.10.	Kidney . . . . .	318
3.11.	Other recommendations . . . . .	318
4.	Future directions . . . . .	319
5.	Concluding remarks . . . . .	319
	Acknowledgments . . . . .	319
	References . . . . .	319

## 1. Definition, nomenclature, and epidemiology

Peroxisomes are membrane-bound organelles found within almost all eukaryotic cells [1]. They are formed through replication by fission (the major pathway for peroxisome formation) or can originate from the endoplasmic reticulum (ER) through a *de novo* process [2]. Contained within the peroxisome matrix of mammalian cells are over 70 distinct enzymes required for normal lipid metabolism and a host of other biochemical processes critical for normal health and development [3].

Peroxisome biogenesis disorders (PBDs) are autosomal recessive disorders that are characterized by defective peroxisome biosynthesis, assembly, and biochemical functions [4]. Although it is estimated that 1 in 50,000 births are affected by PBDs in North America [5], these estimates may increase with the introduction of newborn screening for peroxisomal disorders across the United States [6]. PBDs are primarily caused by mutations in any of 14 different *PEX* genes, which code for peroxins, proteins involved in peroxisome assembly [5,7]. While mutations in *PEX1* account for nearly 70% of all PBD-ZSD cases, another 26% of cases are caused by mutations in *PEX6*, *PEX10*, *PEX12*, or *PEX26*, with the majority of these cases involving *PEX6* mutations [8,9].

PBDs are divided into 2 groups: Zellweger spectrum disorder (PBD-ZSD) and rhizomelic chondrodysplasia punctata type 1 [10,11]. The treatment guidelines presented here will refer only to PBD-ZSD. Prior to the discovery of their shared peroxisomal basis, three different

syndromes were historically described: Zellweger syndrome (ZS), also referred to as cerebrohepatorenal syndrome; neonatal adrenoleukodystrophy (NALD), and infantile Refsum disease (IRD) [12]. We recommend replacing these names with the overall classification of peroxisome biogenesis disorders in the Zellweger spectrum (PBD-ZSD), ranging from severe (ZS), intermediate (NALD), and mild (IRD) phenotypes, respectively. The purpose of this recommendation is to highlight the fact that the individual clinical pictures are along a spectrum of disease severity and often do not fit into the original assigned categories. Additionally, we now also recognize a group of PBD-ZSD patients who do not exhibit the vision and hearing loss usually described in PBD-ZSD, and instead present with peripheral neuropathy and/or cerebellar ataxia [13–15]. Other variant phenotypes continue to be described [16,17]. These patients would be diagnosed as intermediate or mild within the PBD-ZSD spectrum. Table 1 summarizes the clinical features observed in PBD-ZSD based on disease severity and age of symptom appearance. Symptom expression in most patients has an age-dependent component related to disease severity and considerable overlap exists among patients with severe, intermediate and milder phenotypes. Although the relative proportions of certain features were reported in one cohort with a subset of *PEX* genotypes [18], the prevalence and timing of all outcomes amongst PBD-ZSD patients is not yet adequately described, nor is the risk known for individual patients to develop various postnatal features.

**Table 1**  
Clinical features of PBD-ZSD: severity, age of onset, and suggested treatments.

Clinical features	Neonate	1–6 months	6 months–4 years	>4 years	Suggested treatments (if available)
Neuronal migration disorder	S				
Chondrodysplasia punctata	S				
Renal cortical microcysts	S				
Respiratory compromise	S	S			Oxygen support
Craniofacial dysmorphism	S, I	I, M			
Direct hyperbilirubinemia	S, I, M	I, M			
Liver dysfunction, hepatomegaly	S	I, M			Vitamin K supplementation, primary bile acid therapy
Failure to thrive, small size, hypotonia and poor feeding	S, I	I, M	I, M	M	Feeding therapy, G-tube placement, vitamins A, D, E, and K
Seizures	S	I, M	I, M	M	Antiepileptic drugs
Adrenal insufficiency	S	I, M	I, M	M	Hydrocortisone (Cortef)
Cataracts	S	I, M	I, M	M	Cataract removal
Retinal degeneration			I, M	M	Corrective lenses
Sensorineural hearing loss	S	I, M	I, M	M	Hearing aid, cochlear implant
Psychomotor retardation	S	I, M	I, M	M	Physical/occupational therapy
Leukodystrophy		I	I	M	
Osteopenia			I	I, M	Vitamin D, calcium, bisphosphonate treatment
Calcium oxalate renal stones			I, M	I, M	Increased fluid intake, urine alkalinization
Peripheral neuropathy			M	M	
Cerebellar ataxia			M	M	
Enamel hypoplasia				I, M	Bonding, repair of permanent teeth

Abbreviations: S, severe; I, intermediate; M, mild; G-tube, gastrostomy tube.

## 2. Laboratory diagnostic criteria

### 2.1. Traditional biochemical testing

Since their initial discovery, an increasing number of biochemical functions have been ascribed to peroxisomes including  $\beta$ -oxidation of very long chain fatty acids (VLCFA, 24 carbons or longer) and pristanic acid, phytanic acid  $\alpha$ -oxidation, pipecolic acid metabolism, ether glycerolipid (plasmalogen), bile acid biosynthesis, and subcellular localization of catalase (Table 2) [3]. PBDs can be diagnosed by demonstrating abnormalities in several peroxisome biochemical functions that can be monitored in bodily fluids (Fig. 1). The primary step in PBD-ZSD diagnosis generally involves the detection of elevated VLCFA in a fasting plasma sample [19]. Elevations of C26:0 and C26:1 fatty acids and the ratios of C24:0/C22:0 and C26:0/C22:0 are consistent with a peroxisomal fatty acid  $\beta$ -oxidation defect [5]. Although usually abnormal on a blood specimen drawn randomly during the day, equivocal results, for example, in the case of elevated C26:0 with normal or near normal ratios of 24:0/22:0 and 26:0/22:0, and a high total lipid fatty acid content, measurements should be repeated on a plasma sample after overnight fasting. False positive results have rarely been reported, although this can occur if patients are on a ketogenic diet [20,21]. Additional studies demonstrating defects in multiple peroxisome enzyme pathways are necessary to diagnose PBD-ZSD, such as measurement of the methyl-branched fatty acids phytanic and pristanic acids, erythrocyte plasmalogens, pipecolic acid in plasma and/or urine, and the bile acid intermediates dihydroxycholestanic acid (DHCA) and trihydroxycholestanic acid (THCA) in plasma and/or urine [11]. Reduced levels of erythrocyte plasmalogens, whose biosynthesis is dependent on peroxisome function, may be observed depending on disease severity [5]. It should be noted that pipecolic acid levels are more likely to be abnormal in urine in the newborn period, and more abnormal in plasma in later ages [22–24]. Additionally, phytanic and pristanic acids may not be elevated in newborn infants who are not consuming dairy products or other dietary sources of these fatty acids [19]. Owing to defective biosynthesis in liver peroxisomes of the final C24 bile acids, cholic and deoxycholic acids, there is elevation of C27 bile acid intermediates, DHCA and THCA, in blood and urine [3].

Biochemical testing of skin fibroblasts is useful to confirm the metabolite abnormalities seen in the blood and urine and clarify questionable results in body fluids. The biochemical assays most frequently used in fibroblasts involve quantifying phytanic and pristanic acid oxidation, VLCFA accumulation and/or oxidation and plasmalogen biosynthesis [19]. Cultured skin fibroblasts are also valuable for establishing the subcellular localization of peroxisomal matrix proteins, such as catalase, which can distinguish PBD-ZSD from phenotypically similar peroxisomal single enzyme deficiencies [25].

Approximately 10–15% of suspected PBD-ZSD patients with elevated VLCFAs will not have PBD-ZSD, but a single  $\beta$ -oxidation enzyme defect in very long chain acyl-CoA oxidase (*ACOX1*) [26] or D-bifunctional protein (*HSD17B4*) [27]. The clinical phenotypes of these patients

overlap that of PBD-ZSD. Other overlapping phenotypes include single enzyme/protein defects in branched chain fatty acid and bile acid metabolism, including  $\alpha$ -methyl-acyl CoA racemase (*AMACR*) [28], phytanoyl-Coenzyme A hydroxylase (*PHYH*) [29], *PEX7* [30] and sterol carrier protein X (*SCPx*) [31].

It is important to not rely on VLCFA screening alone for patients who are strongly suspected to have PBD-ZSD. In a small number of cases, mutations in *PEX* genes such as *PEX2*, *PEX10*, *PEX12*, *PEX16* and *PEX11B* have been identified in patients with mild or absent elevations in VLCFA [9,13,32–35]. Consequently, testing for multiple biochemical functions in patients or obtaining biochemical studies on patient-derived fibroblasts and genetic testing may be necessary for proper diagnosis.

### 2.2. Genetic diagnostic testing

Next-generation sequencing panels for *PEX* genes are being used more frequently as a confirmatory test, and may be required for peroxisome disorders that are difficult to resolve by traditional biochemical methods [16,17,34,36–38]. These DNA tests are available on a clinical basis. Identification of mutations may have prognostic value [39]. For example, patients with two *PEX* null alleles generally have a severe phenotype, and those patients who carry the common *PEX1*-p.G843D allele are predicted to have a milder phenotype [40]. Homozygosity for *PEX1*-p.G843D typically predicts a milder phenotype, but even in this category there is a range of intellectual impairment to normal intellect, indicating that modifier genes, as yet to be identified, are influential [16,18]. The outcome of the combination of a *PEX* null allele with a missense allele can range from intermediate to milder, and this depends on the residual function of the missense allele. In a recent publication [17], certain missense alleles in *PEX1* and *PEX6*, in combination with null alleles, defined a group of PBD-ZSD patients with normal intellect. In addition, patients with mutations in the region encoding the zinc finger domain of *PEX2*, *PEX12* and *PEX10*, and certain mutations in *PEX16* [13–15] exhibit variant phenotypes. In contrast to biochemical tests, mutation analysis will also identify heterozygous carriers, which will allow reliable genetic counseling of families and may assist with eligibility for future clinical trials.

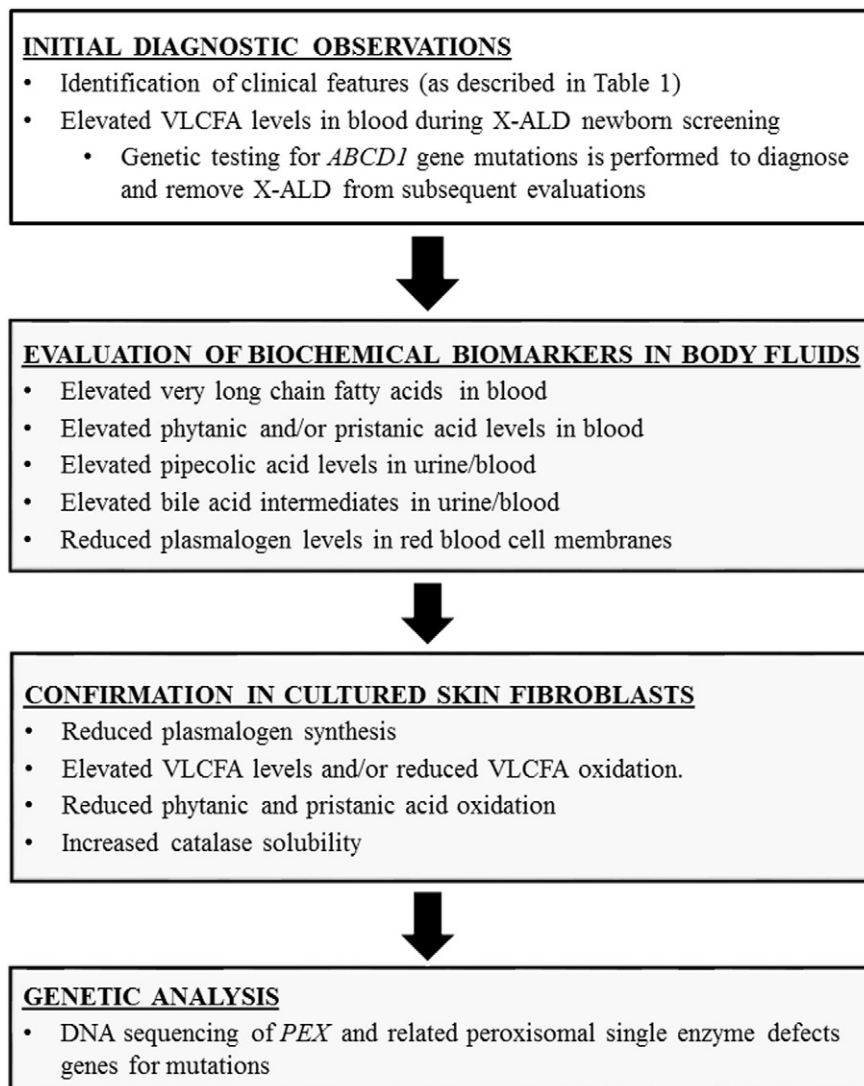
### 2.3. Newborn screening

The combination of liquid chromatography and tandem mass spectrometry (LC-MS/MS) to detect elevated levels of VLCFAs in newborn blood spots has been validated as a diagnostic approach for X-linked adrenoleukodystrophy (X-ALD), a related peroxisomal disorder [6,41,42]. Legislation for X-ALD newborn screening has passed in New Jersey, Connecticut, Illinois, Tennessee and California and screening has begun in New York; continued legislative efforts are expected to expand through movements initiated by patient families and advocacy organizations to lobby their state legislatures. Recently, the Department of Health and Human Services Advisory Committee for Heritable Disorders for

**Table 2**  
Diagnostically useful tests of peroxisome function in PBD-ZSD.

Peroxisomal function	Tissue/cells tested	Findings in PBD-ZSD
$\beta$ -Oxidation of VLCFA	Plasma/cultured fibroblasts	Elevated VLCFA in plasma, cells; deficient VLCFA oxidation in cells
$\beta$ -Oxidation of branched-chain fatty acids (pristanic acid)	Plasma/cultured fibroblasts	Elevated pristanic acid in plasma; deficient pristanic acid oxidation in cells
$\alpha$ -Oxidation of branched-chain fatty acids (phytanic acid)	Plasma/cultured fibroblasts	Elevated phytanic acid in plasma; deficient phytanic acid oxidation in cells
Ether glycerolipid (plasmalogen) biosynthesis	RBC/cultured fibroblasts	Deficiency of RBC plasmalogens; deficient biosynthesis of plasmalogens in cells
Bile acid synthesis	Plasma/urine	Accumulation of C27 bile acids, DHCA and THCA
Pipecolic acid oxidation	Plasma/urine	Elevated pipecolic acid in plasma and urine
Catalase subcellular localization	Fibroblasts	Deficient peroxisomal catalase and elevated cytosolic catalase

Abbreviations: PBD-ZSD, peroxisome biogenesis disorder-Zellweger spectrum disorder; RBC, red blood cell; VLCFA, very long-chain fatty acids; DHCA, dihydroxycholestanic acid; THCA, trihydroxycholestanic acid.



**Fig. 1.** Diagnostic criteria flowchart for PBD-ZSD. Given the current availability of next generation sequencing panels, clinicians have moved from evaluation of biochemical markers to genetic analysis future reproductive options, carrier testing in relatives, eligibility purposes in clinical trials and for patients that are difficult to diagnose. In difficult cases, it may still be necessary to evaluate cultured fibroblasts, and this may be important also to ascertain responses of specific mutations for future interventional trials. Abbreviations: PBD-ZSD, peroxisome biogenesis disorder-Zellweger spectrum disorder; X-ALD, X-linked adrenoleukodystrophy; VLCFA, very long chain fatty acids.

Newborns and Children voted to propose the addition of X-ALD screening in the Recommend Uniform Screening Panel. The implications of X-ALD newborn screening include the ability to perform clinical surveillance for early detection of symptom onset and treatment for affected males and counseling for carrier females [43]. Newborn screening for X-ALD should also detect the majority of PBD-ZSD cases that feature elevated blood VLCFA levels, thereby permitting early diagnosis and determination of accurate incidence estimates. As newborn screening expands in the future, the diagnostic approach for PBD-ZSDs will necessarily be revised toward more confirmatory testing as seen in other newborn screening diseases. It is anticipated that the clinical phenotype of PBD-ZSD will be expanded as variant patients are identified.

#### 2.4. Prenatal diagnosis of PBD-ZSD

Prenatal diagnosis of PBD-ZSD can be accomplished in the first or second trimester using biochemical or genetic testing of chorionic villi cells or cultured amniocytes. Preimplantation genetic diagnosis can also be performed when the *PEX* gene mutations are known [44].

### 3. Management and treatment guidelines

PBD-ZSD is a multi-organ disease, as peroxisomes are involved in critical metabolic pathways in nearly all the cells of the body from fetal development throughout adult life [4]. The wide variation in clinical severity and rate of disease progression adds complexity to the medical management of the group as a whole. With the recognition that some manifestations of PBD-ZSD arise during fetal development and cannot be reversed, particularly any brain dysplasia, therapeutic expectations for some neurologic symptoms must be tempered. Nevertheless, additional medical issues arise postnatally that can benefit from current therapy. At this time, treatment of any manifestations of PBD-ZSD focuses largely on symptomatic or supportive therapies. The following guidelines are meant as a starting point for management of these complex conditions for personalized medical care.

#### 3.1. Clinical evaluations following initial diagnosis

Table 3 summarizes recommended clinical evaluations at the time of the initial diagnosis of PBD-ZSD to establish the extent of disease and later in life as symptoms appear. It is likely that some of the

**Table 3**  
Recommended evaluations for PBD-ZSD patients.

Symptoms	Specific examinations	Suspected findings in severe PBD-ZSD	Suspected findings in intermediate/mild PBD-ZSD
Growth failure	Height, weight and head circumference, nutritional evaluation	Poor growth, feeding difficulties, fat soluble vitamin deficiency	Poor growth, feeding difficulties, fat soluble vitamin deficiency
Deafness	Hearing testing, brainstem auditory evoked responses	Bilateral sensorineural deafness	Progressive bilateral sensorineural hearing loss, deafness
Visual impairment	Ophthalmologic exam, visual fields, fundus photography, OCT	Cataracts, glaucoma, optic nerve hypoplasia	Progressive retinal dystrophy, blindness, band keratopathy
Neurological	Brain MRI, EEG, nerve conduction studies	Hypotonia, neuronal migration defects on MRI, neonatal seizures	Hypotonia, leukodystrophy, cerebellar atrophy on MRI, seizures, peripheral neuropathy, ataxia
Hepatic dysfunction	AST, ALT, GGT, bilirubin, albumin, alkaline phosphatase, bile acids (intermediate C27 and mature C24 bile acids, PT, PTT, abdominal ultrasound)	Hepatomegaly, elevated transaminases, cholestasis, defective synthetic functions, portal hypertension,	Same as severe ZSD, but milder
Renal insufficiency	Serum creatinine, BUN, abdominal ultrasound, urine oxalate	Renal cortical cysts	Calcium oxalate renal stones
Adrenal insufficiency, hyponatremia, hypotension, vomiting	Adrenal function tests, early morning (8 am) cortisol and ACTH, ACTH stimulation test	Progressive adrenal insufficiency	Progressive adrenal insufficiency
Skeletal abnormalities, fractures	X-rays, DXA scan, serum calcium and phosphorous, alkaline phosphatase	Chondrodysplasia punctata, hips and knees	Low bone mineral density, pathological fractures
Dental	Dental exam, X-rays		Enamel hypoplasia of secondary teeth
Psychomotor retardation	Developmental assessment	Few developmental milestones gained	Delayed milestones with broad range of achievement from cognitive delay to normal cognition

Abbreviations: PBD-ZSD, peroxisome biogenesis disorder-Zellweger spectrum disorder; ERG, electroretinogram; OCT, optical coherence tomography; MRI, magnetic resonance imaging; EEG, electroencephalogram; AST, aspartate aminotransferase; ALT, alanine aminotransferase; GGT, gamma-glutamyltransferase; PT, prothrombin time; PTT, partial thromboplastin time; BUN, blood urea nitrogen; ACTH, adrenocorticotropic hormone; DXA, dual-energy x-ray absorptiometry.

recommended evaluations will have been completed by the time a PBD-ZSD diagnosis has been confirmed. Patients should be re-evaluated yearly (or more frequently) to detect progression of disease and begin timely therapy.

Severe PBD-ZSD patients present in the neonatal period and have developmental malformations of the brain, kidneys and skeleton (Table 1). They have a more predictable clinical course than milder forms of PBD-ZSD. There is a characteristic craniofacial dysmorphism that includes an enlarged fontanelle, prominent forehead, epicanthal folds, hypertelorism, a broad, flat nasal bridge and migronathia [5,45]. Neonatal seizures, severe hypotonia and developmental delays are consequent to neuronal migrations defects that characteristically appear as polymicrogyria and heterotopias on brain magnetic resonance imaging [46]. Renal micronodular cortical cysts can be observed by renal ultrasound and are not usually symptomatic. An enlarged liver with dysfunction of the hepatocellular and biliary system is typically present. Due to the severe hypotonia, feeding difficulties are often prominent, as well as laryngomalacia and other respiratory dysfunction [45]. Developmental progress is usually minimal. For seizure control, standard antiepileptic drugs (AED) may be used. No type of AED is contraindicated, although certain medications that have respiratory suppressive effects must be avoided if respiratory compromise is present. Seizures may be difficult to control despite use of appropriate medication. Feeding problems may require the placement of a gastrostomy tube (G-tube). With regards to respiratory therapy, use of nasal cannula for oxygen may be necessary as the disease progresses. The transition to a more aggressive type of respiratory support is a decision that should be discussed between the family and medical care team with informed expectations about survival and quality of life. Overall, for severe PBD-ZSD, seizure control, feeding and respiratory support are often the main focus for management, although additional interventions as described below may also be valuable for quality of life.

For the majority of patients who present with intermediate or milder PBD-ZSD, the details of the management are discussed below.

### 3.2. Feeding and nutrition

Many PBD-ZSD children have significant food selectivity and the involvement of a behavioral feeding program is often indicated in the older PBD-ZSD child. Supplying adequate calorie intake for affected children may entail the placement of a G-tube to allow simpler home management. With many children having some degree of malabsorption due to bile acid deficiency, elemental formulas may be better tolerated.

Currently, there is no specific diet that is recommended for PBD-ZSD patients. Although VLCFA levels are elevated in the tissues and body fluids of PBD-ZSD patients, it is unclear as to whether a reduction in dietary VLCFA will prevent the progression of the disease or its associated symptoms [47]. A reduction in dietary VLCFA alone has not been shown to reduce blood VLCFA levels [48], as the body produces most VLCFA endogenously. Plasma VLCFA levels are decreased only by the combination of dietary reduction of VLCFA and supplementation with Lorenzo's oil (a 4:1 mixture of glyceryl trioleate and glyceryl trierucate) in X-ALD patients [49], but this does not affect the progression of an already established leukodystrophy [50–52]. Moreover, increased dietary monounsaturated fatty acids in Lorenzo's oil may be contraindicated in PBD-ZSD patients who already accumulate large amounts of C26:1 due to defective VLCFA oxidation [53]. Finally, the effects of these dietary interventions have not been studied in PBD-ZSD patients.

Phytanic acid is a methyl branched-chain fatty acid exclusively obtained from dietary sources such as ruminant fats, dairy products, and certain fish [54]. As such, it can be eliminated by dietary restriction [54]. There is a minor amount of phytanic acid in human breast milk [55]. Dietary restriction of phytanic acid might be considered, since high phytanic acid levels over time could contribute to disease through mechanisms similar to that observed in adult Refsum disease [56,57]. In contrast to most patients with adult Refsum disease, however, PBD-ZSD patients tend to have normal or lower plasma phytanic acid levels [58] and no studies have demonstrated specific effects of phytanic acid accumulation from other peroxisomal defects in PBD-ZSD patients.

Until definitive studies are conducted, it seems reasonable to monitor plasma phytanic acid levels and consider dietary modification if levels become excessive.

Since PBD-ZSD patients have impaired endogenous synthesis of docosahexaenoic acid (DHA) [59], and DHA is important in brain and retinal development and function, supplementation with DHA, was previously recommended. However, a placebo-controlled study showed no clinical benefit of DHA supplementation in enrolled patients in the PBD-ZSD spectrum. [60]. Owing to defective bile acid synthesis, supplements of the fat-soluble vitamins, A, D, E, and K are recommended.

### 3.3. Liver

To help support liver function, supplementation of vitamin K at a dose of 2.5 mg–5 mg per day is recommended. Bile acid metabolism is altered in PBD-ZSD [61,62], and primary bile acid therapy (cholic acid and chenodeoxycholic acid) may improve liver function by reducing the accumulation of abnormal bile acid precursors, such as DHCA and THCA [63,64]. Recently, cholic acid (Cholbam) has been approved by the United States Food and Drug Administration to treat peroxisomal disorders, including PBD-ZSD [65]. The available studies evaluating the effectiveness of bile acid therapy in PBD-ZSD are limited and may have differential effects depending on the severity of the disease. Coagulation factors and other synthetic liver functions should be monitored. Persons with overt liver dysfunction require more frequent monitoring and may benefit from referral to a gastroenterologist. Liver dysfunction may lead to varices that respond to appropriate therapies.

### 3.4. Hearing

Many patients with PBD-ZSD have some degree of hearing loss [66]; auditory functions should therefore be evaluated annually in children affected with PBD-ZSD. Hearing aids should be used in children found to have substantive hearing loss. Cochlear implants have been effectively placed in PBD-ZSD children when hearing loss is severe and cannot be compensated by hearing aids. In such instances, improvements in environmental awareness, and in some circumstances, speech, have been frequently noted in other syndromes with congenital deafness [67].

### 3.5. Vision

Vision loss is commonly seen with PBD-ZSD due to retinal dystrophy and optic nerve abnormalities [16,68,69]. Therefore, periodic ophthalmologic evaluations are indicated. Although cataracts are rare, if present, their removal in early infancy may preserve vision with the understanding that retinal dysfunction may later develop. Glasses should be used, as needed, to correct refractive errors. In children with confirmed PBD-ZSD, there appears to be no value in performing multiple electroretinograms (ERG) to assess functional vision. ERG testing has not been demonstrated to be predictive of vision and does not provide an index of progression [60]. Performing optical coherence tomography in children who can cooperate by looking directly at a light source may be useful for defining and monitoring retinal health. For children with both hearing and vision impairment, enrollment in the deaf-blind community is strongly encouraged. Appropriate resources include the National Family Association for Deaf-Blind (<http://www.nfadb.org>) and the National Center on Deaf-Blindness (<https://nationaldb.org>), which can provide connections to individual state deaf-blind projects.

### 3.6. Neurological function

Seizures have been observed in the neonatal period in nearly all severely affected PBD-ZSD patients [70], and have been reported in 23% of less severe patients [18]. EEGs can determine the frequency and duration of seizures and should be performed whenever changes in seizure activity are suspected. Common medications used to control

seizures in children affected by PBD-ZSD are levetiracetam, phenobarbital, clonazepam, topiramate, and lamotrigine.

PBD-ZSD patients can also develop a leukodystrophy [18,64], which can be silent, arrested or progressive. We recommend a baseline MRI of the brain, followed by additional studies if clinically indicated. Identification of white matter changes can have prognostic significance for changes in cognitive, behavioral and/or motor abilities.

Evaluation for early physical, occupational and speech therapy is recommended for all children with PBD-ZSD. Therefore, early intervention services should be provided.

### 3.7. Bone

Children with severe PBD-ZSD may have chondrodysplasia punctata or stippling seen at the growth plates. Decreased bone mineral density that worsens over time is associated with intermediate and milder forms of PBD-ZSD and pathologic fractures have occurred in some patients with no evidence of trauma. The incidence of bone disease in the course of PBD-ZSD has not been systematically studied. In patients who are older than 1 year and are non-weight bearing, or have had previous fractures, evaluation for bone disease should be considered. This should include dual-energy x-ray absorptiometry (DXA) that has been well-validated in pediatric patients. Evaluation of vitamin D status is also recommended. At the discretion of the clinician, markers of bone turnover such as phosphorus and parathyroid hormone levels may also be evaluated.

Regarding treatment of bone disease in PBD-ZSD, a recent study has reported successful treatment with bisphosphonate medications in a PBD-ZSD patient [71]. Bisphosphonate therapy should be carefully considered in consultation with an experienced metabolic bone specialist. Additionally, weight bearing physical activity has shown to slow bone loss in children and therefore prevent fractures [72].

### 3.8. Teeth

Dental examination should be performed every 6 months. Many children with PBD-ZSD have enamel abnormalities of permanent teeth and should receive appropriate dental care [73–75].

### 3.9. Adrenal insufficiency

As with other peroxisomal disorders, particularly X-ALD, primary adrenal insufficiency has occurred in PBD-ZSD. A recent study reported a high prevalence of primary adrenal insufficiency in a population of 29 PBD-ZSD patients [76]. It is recommended that after one year of age, yearly (or more frequent) adrenal monitoring with adrenocorticotropic hormone (ACTH) and morning cortisol be performed. Treatment with adrenal replacement using standard dosing should be instituted if abnormal. Families and clinicians should be aware of the possibility of adrenal insufficiency and consider stress dosing in periods of sudden severe illness, fever, and major surgical procedures.

### 3.10. Kidney

Children affected by PBD-ZSD, particularly older children ( $\geq 4$ –6 years), should be monitored for hyperoxaluria, which can lead to kidney stone formation and renal failure [77]. This can be determined by measuring oxalic acid and creatinine in the urine. Kidney ultrasound may be useful to detect renal stones.

### 3.11. Other recommendations

It is also recommended that all patients on the PBD-ZSD spectrum should be vaccinated against influenza and respiratory syncytial virus yearly, in addition to the normal course of vaccination for other childhood diseases.

#### 4. Future directions

The treatment guidelines discussed herein provide a starting point for the personalized management of PBD-ZSD based on current medical practice; however, we anticipate these guidelines will evolve over time as emerging therapeutic strategies for PBDs are tested in laboratory settings and eventually in clinical trials. A robust portfolio of *in vitro* and whole organism models of PBD-ZSD provides the basis for laboratory research. Cultured patient cells, including skin fibroblasts, have provided invaluable for screening and testing drug therapies *in vitro* [78]. Most recently, PBD-ZSD patient-derived skin fibroblasts have been reprogrammed into induced pluripotent stem cells (iPSCs) that were differentiated into neural and hepatic cell models of disease that could be used in drug screening and testing efforts [79]. There are several genetically engineered mouse models of *PEX* gene defects [80], including a model of the common *PEX1* p.G843D mutation [81]. In addition, a host of invertebrate models of PBD-ZSD exist including genetically engineered worms, fruit flies, and zebrafish [82]. All provide opportunities to screen for and/or test specific therapies on the scale of the whole organism.

The principal strategies being actively pursued include high-content screening of large chemical libraries for compounds that improve peroxisome assembly and function, as well as gene and cellular therapies. Seminal screening studies identified betaine as a potential molecular chaperone that can improve peroxisome assembly in cultured cells from PBD-ZSD patients with *PEX1* p.G843D mutations [78]. Candidate drug screens identified arginine as another potential molecular chaperone in patient cell lines [83]. Larger-scale drug screens are currently being conducted at the National Center for Advancing Translational Sciences at the National Institutes of Health (Hacia, personal communication). Advances in gene therapy, including the emergence of adeno-associated virus (AAV) gene delivery systems, provide hope for the treatment of numerous genetic disorders, including PBD-ZSD. Multiple successful retinal gene augmentation trials for Leber congenital amaurosis (LCA) [84], a rare inherited eye disease, is of special relevance of PBD-ZSD. Currently, AAV9-mediated gene augmentation therapy for vision loss in PBD-ZSD is being developed and will be tested in mouse models of milder forms of PBD-ZSD (Bennett, personal communication). Given that PBD-ZSD is a multi-systemic disease, gene therapy aimed at correcting peroxisome assembly in other organs, most notably the central nervous system (CNS) and the liver, is of great interest to the medical research community. Finally, we recognize potential therapeutic opportunities for cellular therapies, including the transplant of cell types and cell lineages affected in PBD-ZSD patients.

#### 5. Concluding remarks

With greater understanding of the full range of severity seen in PBD-ZSD, physicians can transition to a more targeted approach to supportive therapies. Vision and hearing interventions, nutrition provisions, along with monitoring for adrenal insufficiency, renal stones, bone density and dental enamel defects, can all enhance quality of life for PBD-ZSD patients. Further research into all of the variation in PBD-ZSD children is urgently needed in order to provide more evidence-based guidelines. Our established ongoing longitudinal natural history study on PBD-ZSD will help us acquire and disseminate information regarding this disease, and to identify accurate clinical endpoints for future interventional trials (<https://clinicaltrials.gov/ct2/show/NCT01668186?term=NCT01668186&rank=1>).

#### Acknowledgments

The authors wish to acknowledge Ms. Heidi Harris, Ms. Shannon Butalla and Ms. Melissa Gamble for their assistance in the preparation of this manuscript.

#### References

- [1] M. Islinger, S. Grille, H.D. Fahimi, M. Schrader, The peroxisome: an update on mysteries, *Histochem. Cell Biol.* 137 (5) (2012) 547–574, <http://dx.doi.org/10.1007/s00418-012-0941-4>.
- [2] G. Agrawal, S. Subramani, Emerging role of the endoplasmic reticulum in peroxisome biogenesis, *Front. Physiol.* 4 (2013) 286, <http://dx.doi.org/10.3389/fphys.2013.00286>.
- [3] R.J. Wanders, H.R. Waterham, Biochemistry of mammalian peroxisomes revisited, *Annu. Rev. Biochem.* 75 (2006) 295–332, <http://dx.doi.org/10.1146/annurev.biochem.74.082803.133329>.
- [4] N.E. Braverman, M.D. D'Agostino, G.E. Maclean, Peroxisome biogenesis disorders: Biological, clinical and pathophysiological perspectives, *Dev. Disabil. Res. Rev.* 17 (3) (2013) 187–196, <http://dx.doi.org/10.1002/ddrr.1113>.
- [5] S.J. Steinberg, G. Dodt, G.V. Raymond, N.E. Braverman, A.B. Moser, H.W. Moser, Peroxisome biogenesis disorders, *Biochim. Biophys. Acta* 1763 (12) (2006) 1733–1748, <http://dx.doi.org/10.1016/j.bbamcr.2006.09.010>.
- [6] C. Theda, K. Gibbons, T.E. Defor, P.K. Donohue, W.C. Golden, A.D. Kline, F. Gulamali-Majid, S.R. Panny, W.C. Hubbard, R.O. Jones, A.K. Liu, A.B. Moser, G.V. Raymond, Newborn screening for X-linked adrenoleukodystrophy: further evidence high throughput screening is feasible, *Mol. Genet. Metab.* 111 (1) (2014) 55–57, <http://dx.doi.org/10.1016/j.ymgme.2013.10.019>.
- [7] M.S. Eberink, J. Koster, G. Visser, F. Spronsen, I. Stolte-Dijkstra, G.P. Smit, J.M. Fock, S. Kemp, R.J. Wanders, H.R. Waterham, A novel defect of peroxisome division due to a homozygous non-sense mutation in the *PEX11* beta gene, *J. Med. Genet.* 49 (5) (2012) 307–313, <http://dx.doi.org/10.1136/jmedgenet-2012-100778>.
- [8] W.Y. Yik, S.J. Steinberg, A.B. Moser, H.W. Moser, J.G. Hacia, Identification of novel mutations and sequence variation in the Zellweger syndrome spectrum of peroxisome biogenesis disorders, *Hum. Mutat.* 30 (3) (2009) E467–E480, <http://dx.doi.org/10.1002/humu.20932>.
- [9] M.S. Eberink, P.A. Mooijer, J. Gootjes, J. Koster, R.J. Wanders, H.R. Waterham, Genetic classification and mutational spectrum of more than 600 patients with a Zellweger syndrome spectrum disorder, *Hum. Mutat.* 32 (1) (2011) 59–69, <http://dx.doi.org/10.1002/humu.21388>.
- [10] N.E. Braverman, A.B. Moser, S.J. Steinberg, Rhizomelic chondrodysplasia punctata type 1, in: R.A. Pagon, M.P. Adam, H.H. Ardinger, et al., (Eds.), *GeneReviews*® [Internet], University of Washington, Seattle, WA, Nov 16 2001 (1993–2015). Available from: <http://www.ncbi.nlm.nih.gov/books/NBK1270/>, Updated 2012 Sep 13).
- [11] S.J. Steinberg, G.V. Raymond, N.E. Braverman, A.B. Moser, Peroxisome biogenesis disorders, Zellweger syndrome spectrum, in: R.A. Pagon, M.P. Adam, H.H. Ardinger, et al., (Eds.), *GeneReviews*® [Internet], University of Washington, Seattle, WA, Dec 12 2003 (1993–2015). Available from: <http://www.ncbi.nlm.nih.gov/books/NBK1448/>, Updated 2012 May 10).
- [12] H. Zellweger, P. Maertens, D. Superneau, W. Wertenlecker, History of the cerebrohepato-renal syndrome of Zellweger and other peroxisomal disorders, *South. Med. J.* 81 (3) (1988) 357–364.
- [13] M.S. Eberink, B. Csanyi, W.K. Chong, S. Denis, P. Sharp, P.A. Mooijer, C.J. Dekker, C. Spooner, L.H. Ngu, C. De Sousa, R.J. Wanders, M.J. Fietz, P.T. Clayton, H.R. Waterham, S. Ferdinandusse, Identification of an unusual variant peroxisome biogenesis disorder caused by mutations in the *PEX16* gene, *J. Med. Genet.* 47 (9) (2010) 608–615, <http://dx.doi.org/10.1136/jmg.2009.074302>.
- [14] L. Regal, M.S. Eberink, N. Goemans, R.J. Wanders, L. De Meirleir, J. Jaeken, M. Schrooten, R. Van Coster, H.R. Waterham, Mutations in *PEX10* are a cause of autosomal recessive ataxia, *Ann. Neurol.* 68 (2) (2010) 259–263, <http://dx.doi.org/10.1002/ana.22035>.
- [15] C. Sevin, S. Ferdinandusse, H.R. Waterham, R.J. Wanders, P. Aubourg, Autosomal recessive cerebellar ataxia caused by mutations in the *PEX2* gene, *Orphanet J. Rare Dis.* 6 (2011) 8, <http://dx.doi.org/10.1186/1750-1172-6-8>.
- [16] J. Majewski, Z. Wang, I. Lopez, S. Al Humaid, H. Ren, J. Racine, A. Bazinet, G. Mitchel, N. Braverman, R.K. Koeneke, A new ocular phenotype associated with an unexpected but known systemic disorder and mutation: novel use of genomic diagnostics and exome sequencing, *J. Med. Genet.* 48 (9) (2011) 593–596, <http://dx.doi.org/10.1136/jmedgenet-2011-100288>.
- [17] I. Ratbi, K.D. Falkenberg, M. Sommen, N. Al-Sheqaihi, S. Guaoua, G. Vandeweyer, J.E. Urquhart, K.E. Chandler, S.G. Williams, N.A. Roberts, M. El Alloussi, G.C. Black, S. Ferdinandusse, H. Ramdi, A. Heimler, A. Fryer, S.A. Lynch, N. Cooper, K.R. Ong, C.E. Smith, C.F. Inglehearn, A.J. Mighell, C. Elcock, J.A. Poulter, M. Tischkowitz, S.J. Davies, A. Sefiani, A.A. Mironov, W.G. Newman, H.R. Waterham, G. Van Camp, Heimler syndrome is caused by hypomorphic mutations in the peroxisome biogenesis genes *PEX1* and *PEX6*, *Am. J. Hum. Genet.* 97 (4) (2015) 535–545, <http://dx.doi.org/10.1016/j.ajhg.2015.08.011>.
- [18] B.T. Poll-The, J. Gootjes, M. Duran, J.B. De Klerk, L.J. Wenniger-Prick, R.J. Admiraal, H.R. Waterham, R.J. Wanders, P.G. Barth, Peroxisome biogenesis disorders with prolonged survival: phenotypic expression in a cohort of 31 patients, *Am. J. Med. Genet. A* 126A (4) (2004) 333–338, <http://dx.doi.org/10.1002/ajmg.a.20664>.
- [19] S. Steinberg, R. Jones, C. Tiffany, A. Moser, Investigational methods for peroxisomal disorders, *Curr. Protoc. Hum. Genet.* (2008) <http://dx.doi.org/10.1002/0471142905.hg1706s58> (Chapter 17: p. Unit 17 6).
- [20] T.J. Stradomska, M. Bachanski, J. Pawlowska, M. Syczewska, A. Stolarczyk, A. Tylki-Szymanska, The impact of a ketogenic diet and liver dysfunction on serum very long-chain fatty acids levels, *Lipids* 48 (4) (2013) 405–409, <http://dx.doi.org/10.1007/s11745-013-3761-y>.
- [21] C. Theda, R.C. Woody, S. Naidu, A.B. Moser, H.W. Moser, Increased very long chain fatty acids in patients on a ketogenic diet: a cause of diagnostic confusion, *J. Pediatr.* 122 (5 Pt 1) (1993) 724–726.

- [22] A. Peduto, M.R. Baumgartner, N.M. Verhoeven, D. Rabier, M. Spada, M.C. Nassogne, B.T. Poll-The, G. Bonetti, C. Jakobs, J.M. Saudubray, Hyperpepcolic acidemia: a diagnostic tool for peroxisomal disorders, *Mol. Genet. Metab.* 82 (3) (2004) 224–230, <http://dx.doi.org/10.1016/j.ymgme.2004.04.010>.
- [23] H.R. Waterham, M.S. Eberink, Genetics and molecular basis of human peroxisome biogenesis disorders, *Biochim. Biophys. Acta* 1822 (9) (2012) 1430–1441, <http://dx.doi.org/10.1016/j.bbdis.2012.04.006>.
- [24] S.J. Steinberg, A. Snowden, N.E. Braverman, L. Chen, P.A. Watkins, P.T. Clayton, K.D. Setchell, J.E. Heubi, G.V. Raymond, A.B. Moser, H.W. Moser, A *PEX10* defect in a patient with no detectable defect in peroxisome assembly or metabolism in cultured fibroblasts, *J. Inherit. Metab. Dis.* 32 (1) (2009) 109–119, <http://dx.doi.org/10.1007/s10545-008-0969-8>.
- [25] C. Krause, H. Rosewich, J. Gartner, Rational diagnostic strategy for Zellweger syndrome spectrum patients, *Eur. J. Hum. Genet.* 17 (6) (2009) 741–748, <http://dx.doi.org/10.1038/ejhg.2008.252>.
- [26] S. Ferdinandusse, S. Denis, E.M. Hogenhout, J. Koster, C.W. van Roermund, I.J. L., A.B. Moser, R.J. Wanders, H.R. Waterham, Clinical, biochemical, and mutational spectrum of peroxisomal acyl-coenzyme A oxidase deficiency, *Hum. Mutat.* 28 (9) (2007) 904–912, <http://dx.doi.org/10.1002/humu.20535>.
- [27] D.S. Lieber, S.G. Hershman, N.G. Slate, S.E. Calvo, K.B. Sims, J.D. Schmahmann, V.K. Mootha, Next generation sequencing with copy number variant detection expands the phenotypic spectrum of HSD17B4-deficiency, *BMC Med. Genet.* 15 (2014) 30, <http://dx.doi.org/10.1186/1471-2350-15-30>.
- [28] K. Haugarvoll, S. Johansson, C. Tzoulis, B.I. Haukanes, C. Bredrup, G. Neckelmann, H. Boman, P.M. Knappskog, L.A. Bindoff, MRI characterisation of adult onset alpha-methylacyl-CoA racemase deficiency diagnosed by exome sequencing, *Orphanet J. Rare Dis.* 8 (2013) 1, <http://dx.doi.org/10.1186/1750-1172-8-1>.
- [29] R.J.A. Wanders, H.R. Waterham, B.P. Leroy, Refsum disease, in: R.A. Pagon, M.P. Adam, H.H. Ardinger, et al., (Eds.), *GeneReviews®* [Internet], University of Washington, Seattle, WA, Mar 20 2006 (1993–2015). Available from: <http://www.ncbi.nlm.nih.gov/books/NBK1353/>, Updated 2015 Jun 11.
- [30] A.S. Wierzbicki, Peroxisomal disorders affecting phytanic acid alpha-oxidation: a review, *Biochem. Soc. Trans.* 35 (Pt 5) (2007) 881–886, <http://dx.doi.org/10.1042/BST0350881>.
- [31] S. Ferdinandusse, P. Kostopoulos, S. Denis, H. Rusch, H. Overmars, U. Dillmann, W. Reith, D. Haas, R.J. Wanders, M. Duran, M. Marziniak, Mutations in the gene encoding peroxisomal sterol carrier protein X (SCPx) cause leukoencephalopathy with dystonia and motor neuropathy, *Am. J. Hum. Genet.* 78 (6) (2006) 1046–1052, <http://dx.doi.org/10.1086/503921>.
- [32] A. Mignarri, C. Vinciguerra, A. Giorgio, S. Ferdinandusse, H. Waterham, R. Wanders, E. Bertini, M.T. Dotti, A. Federico, Zellweger spectrum disorder with mild phenotype caused by *PEX2* gene mutations, *JIMD Rep.* 6 (2012) 43–46, [http://dx.doi.org/10.1007/8904\\_2011\\_102](http://dx.doi.org/10.1007/8904_2011_102).
- [33] C. Ohba, H. Osaka, M. Iai, S. Yamashita, Y. Suzuki, N. Aida, N. Shimozawa, A. Takamura, H. Doi, A. Tomita-Katsumoto, K. Nishiyama, Y. Tsurusaki, M. Nakashima, N. Miyake, Y. Eto, F. Tanaka, N. Matsumoto, H. Saito, Diagnostic utility of whole exome sequencing in patients showing cerebellar and/or vermis atrophy in childhood, *Neurogenetics* 14 (3–4) (2013) 225–232, <http://dx.doi.org/10.1007/s10048-013-0375-8>.
- [34] M. Schabhuhtl, T. Wieland, J. Senderek, J. Baets, V. Timmerman, P. De Jonghe, M.M. Reilly, K. Stieglbauer, E. Laich, R. Windhager, W. Erwa, S. Trajanoski, T.M. Strom, M. Auer-Grumbach, Whole-exome sequencing in patients with inherited neuropathies: outcome and challenges, *J. Neurol.* 261 (5) (2014) 970–982, <http://dx.doi.org/10.1007/s00415-014-7289-8>.
- [35] A. Zeharia, M.S. Eberink, R.J. Wanders, H.R. Waterham, A. Gutman, A. Nissenkorn, S.H. Korman, A novel *PEX12* mutation identified as the cause of a peroxisomal biogenesis disorder with mild clinical phenotype, mild biochemical abnormalities in fibroblasts and a mosaic catalase immunofluorescence pattern, even at 40 degrees C, *J. Hum. Genet.* 52 (7) (2007) 599–606, <http://dx.doi.org/10.1007/s10038-007-0157-y>.
- [36] S. Levesque, C. Morin, S.P. Guay, J. Villeneuve, P. Marquis, W.Y. Yik, S. Jiralerspong, L. Bouchard, S. Steinberg, J.G. Hacia, K. Dewar, N.E. Braverman, A founder mutation in the *PEX6* gene is responsible for increased incidence of Zellweger syndrome in a French Canadian population, *BMC Med. Genet.* 13 (2012) 72, <http://dx.doi.org/10.1186/1471-2350-13-72>.
- [37] Y. Sun, L. Wang, X. Wei, Q. Zhu, Y. Yang, Z. Lan, N. Qu, Y. Chu, Y. Wang, S. Yang, Y. Liang, W. Wang, X. Yi, Analysis of a Chinese pedigree with Zellweger syndrome reveals a novel *PEX1* mutation by next-generation sequencing, *Clin. Chim. Acta* 417 (2013) 57–61, <http://dx.doi.org/10.1016/j.cca.2012.12.005>.
- [38] R. Buchert, H. Tawamie, C. Smith, S. Uebe, A.M. Innes, B. Al Hallak, A.B. Ekici, H. Sticht, B. Schwarze, R.E. Lamont, J.S. Parboosingh, F.P. Bernier, R. Abou Jamra, A peroxisomal disorder of severe intellectual disability, epilepsy, and cataracts due to fatty acyl-CoA reductase 1 deficiency, *Am. J. Hum. Genet.* 95 (5) (2014) 602–610, <http://dx.doi.org/10.1016/j.ajhg.2014.10.003>.
- [39] H. Rosewich, A. Ohlenbusch, J. Gartner, Genetic and clinical aspects of Zellweger spectrum patients with *PEX1* mutations, *J. Med. Genet.* 42 (9) (2005), e58, <http://dx.doi.org/10.1136/jmg.2005.033324>.
- [40] C. Walter, J. Gootjes, P.A. Mooijer, H. Portsteffen, C. Klein, H.R. Waterham, P.G. Barth, J.T. Epplen, W.H. Kunau, R.J. Wanders, G. Dodt, Disorders of peroxisome biogenesis due to mutations in *PEX1*: phenotypes and *PEX1* protein levels, *Am. J. Hum. Genet.* 69 (1) (2001) 35–48, <http://dx.doi.org/10.1086/321265>.
- [41] W.C. Hubbard, A.B. Moser, A.C. Liu, R.O. Jones, S.J. Steinberg, F. Lorey, S.R. Panny, R.F. Vogt Jr., D. Macaya, C.T. Turgeon, S. Tortorelli, G.V. Raymond, Newborn screening for X-linked adrenoleukodystrophy (X-ALD): validation of a combined liquid chromatography-tandem mass spectrometric (LC-MS/MS) method, *Mol. Genet. Metab.* 97 (3) (2009) 212–220, <http://dx.doi.org/10.1016/j.ymgme.2009.03.010>.
- [42] B.H. Vogel, S.E. Bradley, D.J. Adams, K. D'Aco, R.W. Erbe, C. Fong, A. Iglesias, D. Kronn, P. Levy, M. Morrissey, J. Orsini, P. Parton, J. Pellegrino, C.A. Saavedra-Matiz, N. Shur, M. Wasserstein, G.V. Raymond, M. Caggana, Newborn screening for X-linked adrenoleukodystrophy in New York State: diagnostic protocol, surveillance protocol and treatment guidelines, *Mol. Genet. Metab.* 114 (4) (2015) 599–603, <http://dx.doi.org/10.1016/j.ymgme.2015.02.002>.
- [43] G.V. Raymond, R.O. Jones, A.B. Moser, Newborn screening for adrenoleukodystrophy: implications for therapy, *Mol. Diagn. Ther.* 11 (6) (2007) 381–384.
- [44] M. Al-Sayed, S. Al-Hassan, M. Rashed, M. Qeba, S. Coskun, Preimplantation genetic diagnosis for Zellweger syndrome, *Fertil. Steril.* 87 (6) (2007) 1468, <http://dx.doi.org/10.1016/j.fertnstert.2006.09.014> (e1-3).
- [45] P.R. Lee, G.V. Raymond, Child neurology: Zellweger syndrome, *Neurology* 80 (20) (2013) e207–e210, <http://dx.doi.org/10.1212/WNL.0b013e3182929f8e>.
- [46] A.J. Barkovich, W.W. Peck, MR of Zellweger syndrome, *AJNR Am. J. Neuroradiol.* 18 (6) (1997) 1163–1170.
- [47] M.A. Van Duyn, A.E. Moser, F.R. Brown III, N. Sacktor, A. Liu, H.W. Moser, The design of a diet restricted in saturated very long-chain fatty acids: therapeutic application in adrenoleukodystrophy, *Am. J. Clin. Nutr.* 40 (2) (1984) 277–284.
- [48] F.R. Brown III, M.A. Van Duyn, A.B. Moser, J.D. Schulman, W.B. Rizzo, R.D. Snyder, J.V. Murphy, S. Kamoshita, C.J. Migeon, H.W. Moser, Adrenoleukodystrophy: effects of dietary restriction of very long chain fatty acids and of administration of carnitine and clofibrate on clinical status and plasma fatty acids, *Johns Hopkins Med. J.* 151 (4) (1982) 164–172.
- [49] A.B. Moser, J. Borel, A. Odone, S. Naidu, D. Cornblath, D.B. Sanders, H.W. Moser, A new dietary therapy for adrenoleukodystrophy: biochemical and preliminary clinical results in 36 patients, *Ann. Neurol.* 21 (3) (1987) 240–249, <http://dx.doi.org/10.1002/ana.410210305>.
- [50] P. Aubourg, C. Adamsbaum, M.C. Lavallard-Rousseau, F. Rocchiccioli, N. Cartier, I. Jambaque, C. Jakobczak, A. Lemaitre, F. Boureau, C. Wolf, et al., A two-year trial of oleic and erucic acids ("Lorenzo's oil") as treatment for adrenomyeloneuropathy, *N. Engl. J. Med.* 329 (11) (1993) 745–752, <http://dx.doi.org/10.1056/NEJM199309093291101>.
- [51] W.B. Rizzo, R.T. Leshner, A. Odone, A.L. Dammann, D.A. Craft, M.E. Jensen, S.S. Jennings, S. Davis, R. Jaitly, J.A. Sgro, Dietary erucic acid therapy for X-linked adrenoleukodystrophy, *Neurology* 39 (11) (1989) 1415–1422.
- [52] G. Uziel, E. Bertini, P. Bardelli, M. Rimoldi, M. Gambetti, Experience on therapy of adrenoleukodystrophy and adrenomyeloneuropathy, *Dev. Neurosci.* 13 (4–5) (1991) 274–279.
- [53] A.E. Moser, I. Singh, F.R. Brown III, G.I. Solish, R.I. Kelley, P.J. Benke, H.W. Moser, The cerebrohepato-renal (Zellweger) syndrome. Increased levels and impaired degradation of very-long-chain fatty acids and their use in prenatal diagnosis, *N. Engl. J. Med.* 310 (18) (1984) 1141–1146, <http://dx.doi.org/10.1056/NEJM198405033101802>.
- [54] P.A. Watkins, A.B. Moser, C.B. Toomer, S.J. Steinberg, H.W. Moser, M.W. Karaman, K. Ramaswamy, K.D. Siegmund, D.R. Lee, J.J. Ely, O.A. Ryder, J.G. Hacia, Identification of differences in human and great ape short-chain acid metabolism that could influence gene expression profiles and physiological functions, *BMC Physiol.* 10 (2010) 19, <http://dx.doi.org/10.1186/1472-6793-10-19>.
- [55] H. Egge, U. Murawski, P. Gyorgy, F. Zilliken, Minor constituents of human milk (I) identification of cyclohexaneundecanoic acid and phytanic acid in human milk fat by a combination gas chromatograph-mass spectrometer, *FEBS Lett.* 2 (4) (1969) 255–258.
- [56] J.H. Millar, Refsum disease—the effect of diet, *Ulster Med. J.* 54 (1) (1985) 41–45.
- [57] D. Steinberg, C.E. Mize, J.H. Herndon Jr., H.M. Fales, W.K. Engel, F.Q. Vroom, Phytanic acid in patients with Refsum's syndrome and response to dietary treatment, *Arch. Intern. Med.* 125 (1) (1970) 75–87.
- [58] Y. Takemoto, Y. Suzuki, R. Horibe, N. Shimozawa, R.J. Wanders, N. Kondo, Gas chromatography/mass spectrometry analysis of very long chain fatty acids, docosahexaenoic acid, phytanic acid and plasmalogen for the screening of peroxisomal disorders, *Brain Dev.* 25 (7) (2003) 481–487.
- [59] M. Martinez, Abnormal profiles of polyunsaturated fatty acids in the brain, liver, kidney and retina of patients with peroxisomal disorders, *Brain Res.* 583 (1–2) (1992) 171–182.
- [60] A.M. Pakar, J.S. Sunness, N.H. Brereton, L.J. Speedie, L. Albanna, S. Dharmaraj, A.B. Moser, R.O. Jones, G.V. Raymond, Docosahexaenoic acid therapy in peroxisomal diseases: results of a double-blind, randomized trial, *Neurology* 75 (9) (2010) 826–830, <http://dx.doi.org/10.1212/WNL.0b013e3181f07061>.
- [61] P.T. Clayton, Inborn errors of bile acid metabolism, *J. Inherit. Metab. Dis.* 14 (4) (1991) 478–496.
- [62] A.M. Lawson, M.J. Madigan, D. Shortland, P.T. Clayton, Rapid diagnosis of Zellweger syndrome and infantile Refsum's disease by fast atom bombardment-mass spectrometry of urine bile salts, *Clin. Chim. Acta* 161 (2) (1986) 221–231.
- [63] K.D. Setchell, P. Bragetti, L. Zimmer-Nechemias, C. Daugherty, M.A. Pellis, R. Vaccaro, G. Gentili, E. Distrutti, G. Dozzini, A. Morelli, et al., Oral bile acid treatment and the patient with Zellweger syndrome, *Hepatology* 15 (2) (1992) 198–207.
- [64] K. Maeda, A. Kimura, Y. Yamato, H. Nitono, H. Takei, T. Sato, H. Mitsubuchi, T. Murai, T. Kurosawa, Oral bile Acid treatment in two Japanese patients with Zellweger syndrome, *J. Pediatr. Gastroenterol. Nutr.* 35 (2) (2002) 227–230.
- [65] United States Food and Drug Administration, FDA approves Cholbam to treat rare bile acid synthesis disorders [Press Release], 2015 Available at: <http://www.fda.gov/NewsEvents/Newsroom/PressAnnouncements/ucm438572.htm>.
- [66] A.C. Theil, R.B. Schutgens, R.J. Wanders, H.S. Heymans, Clinical recognition of patients affected by a peroxisomal disorder: a retrospective study in 40 patients, *Eur. J. Pediatr.* 151 (2) (1992) 117–120.



- [67] S.J. Broomfield, I.A. Bruce, L. Henderson, R.T. Ramsden, K.M. Green, Cochlear implantation in children with syndromic deafness, *Int. J. Pediatr. Otorhinolaryngol.* 77 (8) (2013) 1312–1316, <http://dx.doi.org/10.1016/j.ijporl.2013.05.022>.
- [68] G.N. Wilson, R.G. Holmes, J. Custer, J.L. Lipkowitz, J. Stover, N. Datta, A. Hajra, Zellweger syndrome: diagnostic assays, syndrome delineation, and potential therapy, *Am. J. Med. Genet.* 24 (1) (1986) 69–82, <http://dx.doi.org/10.1002/ajmg.1320240109>.
- [69] H.M. Hittner, F.L. Kretzer, R.S. Mehta, Zellweger syndrome. Lenticular opacities indicating carrier status and lens abnormalities characteristic of homozygotes, *Arch. Ophthalmol.* 99 (11) (1981) 1977–1982.
- [70] Y. Takahashi, Y. Suzuki, K. Kumazaki, Y. Tanabe, S. Akaboshi, K. Miura, N. Shimozawa, N. Kondo, T. Nishiguchi, K. Terada, T. Orii, Epilepsy in peroxisomal diseases, *Epilepsia* 38 (2) (1997) 182–188.
- [71] E.T. Rush, J.L. Goodwin, N.E. Braverman, W.B. Rizzo, Low bone mineral density is a common feature of Zellweger spectrum disorders, *Mol. Genet. Metab.* 117 (1) (2016) 33–37.
- [72] M. Behringer, S. Gruetzner, M. McCourt, J. Mester, Effects of weight-bearing activities on bone mineral content and density in children and adolescents: a meta-analysis, *J. Bone Miner. Res.* 29 (2) (2014) 467–478, <http://dx.doi.org/10.1002/jbmr.2036>.
- [73] B.S. Acharya, P. Ritwik, G.M. Velasquez, S.J. Fenton, Medical-dental findings and management of a child with infantile Refsum disease: a case report, *Spec. Care Dentist.* 32 (3) (2012) 112–117, <http://dx.doi.org/10.1111/j.1754-4505.2012.00248.x>.
- [74] J. Lertsirivorakul, M. Wongswadiwat, P. Treesuwan, Oral manifestations and dental management of a child with Zellweger syndrome, *Spec. Care Dentist.* 34 (1) (2014) 46–50, <http://dx.doi.org/10.1111/scd.12003>.
- [75] D. Tran, W. Greenhill, S. Wilson, Infantile refsum disease with enamel defects: a case report, *Pediatr. Dent.* 33 (3) (2011) 266–270.
- [76] K. Berendse, M. Engelen, G.E. Linthorst, A.S. van Trotsenburg, B.T. Poll-The, High prevalence of primary adrenal insufficiency in Zellweger spectrum disorders, *Orphanet J. Rare Dis.* 9 (2014) 133, <http://dx.doi.org/10.1186/s13023-014-0133-5>.
- [77] C.S. van Woerden, J.W. Grothoff, F.A. Wijburg, M. Duran, R.J. Wanders, P.G. Barth, B.T. Poll-The, High incidence of hyperoxaluria in generalized peroxisomal disorders, *Mol. Genet. Metab.* 88 (4) (2006) 346–350, <http://dx.doi.org/10.1016/j.ymgme.2006.03.004>.
- [78] R. Zhang, L. Chen, S. Jiralerspong, A. Snowden, S. Steinberg, N. Braverman, Recovery of PEX1-Gly843Asp peroxisome dysfunction by small-molecule compounds, *Proc. Natl. Acad. Sci. U. S. A.* 107 (12) (2010) 5569–5574, <http://dx.doi.org/10.1073/pnas.0914960107>.
- [79] X.M. Wang, W.Y. Yik, P. Zhang, W. Lu, N. Huang, B.R. Kim, D. Shibata, M. Zitting, R.H. Chow, A.B. Moser, S.J. Steinberg, J.G. Hacia, Induced pluripotent stem cell models of Zellweger spectrum disorder show impaired peroxisome assembly and cell type-specific lipid abnormalities, *Stem Cell Res. Ther.* 6 (2015) 158, <http://dx.doi.org/10.1186/s13287-015-0149-3>.
- [80] M. Baes, P.P. Van Veldhoven, Mouse models for peroxisome biogenesis defects and beta-oxidation enzyme deficiencies, *Biochim. Biophys. Acta* 1822 (9) (2012) 1489–1500, <http://dx.doi.org/10.1016/j.bbdis.2012.03.003>.
- [81] S. Hiebler, T. Masuda, J.G. Hacia, A.B. Moser, P.L. Faust, A. Liu, N. Chowdhury, N. Huang, A. Lauer, J. Bennett, P.A. Watkins, D.J. Zack, N.E. Braverman, G.V. Raymond, S.J. Steinberg, The Pex1-G844D mouse: a model for mild human Zellweger spectrum disorder, *Mol. Genet. Metab.* 111 (4) (2014) 522–532, <http://dx.doi.org/10.1016/j.ymgme.2014.01.008>.
- [82] P.P. Van Veldhoven, M. Baes, Peroxisome deficient invertebrate and vertebrate animal models, *Front. Physiol.* 4 (2013) 335, <http://dx.doi.org/10.3389/fphys.2013.00335>.
- [83] K. Berendse, M.S. Ebberink, L. IJlst, B.T. Poll-The, R.J. Wanders, H.R. Waterham, Arginine improves peroxisome functioning in cells from patients with a mild peroxisome biogenesis disorder, *Orphanet J. Rare Dis.* 8 (2013) 138, <http://dx.doi.org/10.1186/1750-1172-8-138>.
- [84] E.A. Pierce, J. Bennett, The status of RPE65 gene therapy trials: safety and efficacy, *Cold Spring Harb. Perspect. Med.* 5 (9) (2015) a017285, <http://dx.doi.org/10.1101/cshperspect.a017285>.